

A RARE CASE OF INTUSSUSCEPTION IN A DAIRY COW

UM CASO RARO DE INTUSSUSCEPÇÃO EM UMA VACA LEITEIRA

Enrico Lippi ORTOLANI¹; José Roberto JULY²; Leydson Formiga FEITOSA³

SUMMARY

A rare case of intussusception in the "pars descendens duodeni" of a three-year-old dairy cow was described. The clinical signs manifested were acute anorexia, drop in the milk yield and cessation of rumination and defecation. Auscultation revealed diminished sounds in the abomasum and intestine but a tympanitic sound over a 6 cm diameter area between the 10th and 12th ribs of the right side was detected. Rectal examination revealed a firm, distended and elasticus viscus in the right anterior quadrant. The final diagnosis was obtained by exploratory laparotomy. A resection of the affected bowel followed by an enteroanastomosis were performed. A medical treatment (antibiotic therapy and rehydration) was given for five days to the cow which made an uneventful recovery. The etiology of the clinical signs presented are discussed.

UNITERMS: Intussusception; Cattle; Treatment

INTRODUCTION

Intussusception can be defined as an acute condition where a section of intestine telescopes into the portion immediately distal to it, occluding its lumen (**intussusciens**) and, by arresting the mesenteric blood supply to the invaginating portion (**intussusceptum**), causes necrosis of the affected segment⁷

A common explanation for the occurrence of intussusception is that a violent or irregular peristaltic wave carries a segment of the gut into the portion immediately distal to it, trapping the proximal segment. A suggested predisposing cause of such an event is feeding upon succulent, heavily fertilized lush forage (PEARSON⁶, 1971). However, in a series of 36 cases treated surgically BOSSHART¹ (1930) found that tumors or inflammatory lesions in the lumen of the intussusception apparently were the cause.

The extra mobility caused by the depth of their mesenteric attachments renders the jejunum and the ileum most likely to be the sites of intussusception^{8,9,10}. The condition is less common in the caecum or ascending colon and is very rare in the duodenum, transverse colon or rectum (SMITH⁹, 1984). This paper describes clinical findings in a dairy cow with intussusception and complete intestinal separation in the descending portion of the duodenum and its correction by surgery.

HISTORY AND CLINICAL FINDINGS

A three-year-old Holstein cow weighing 350 kg was admitted to the Veterinary Hospital of the Faculdade de Medicina Veterinária e Zootecnia da Universidade de São Paulo, Brazil, in December 1987.

The cow had calved six months previously. Its daily food intake consisted of 5.5 kg concentrates and roughage (napier grass - **Pennisetum purpureum**) at "ad libitum" consumption. Sudden onset of anorexia, dramatic drop in the milk yield and cessation of rumination and defecation were the principal clinical signs.

When examined at the hospital, the cow was able to stand but had a depressed demeanour. Its rectal temperature was 38.5 °C, heart rate < 50 beats/min, and rumen contraction was absent. Within few hours, the animal became recumbent, with its head turned against its flanks. Scanty amounts of faeces covered by thickened mucus were passed as described by DERIVAUX; DEWALQUE² (1959). Faeces were very dark and their viscous and greasy appearance was consistent with a high degree of crude fibre digestion.

The right antero-ventral quadrant of the abdomen was distended locally. When viewed from behind the animal, the distension imparted to the abdomen a semi-pear-shaped contour. Aus-

1 - PhD - Faculdade de Medicina Veterinária e Zootecnia da USP, São Paulo, Brasil

2 - DVM - São Paulo - SP

3 - Graduate Student - Faculdade de Medicina Veterinária e Zootecnia da USP, São Paulo, Brasil

cultation revealed that abomasal and intestinal sounds were greatly diminished. However, tympanitic sound (“ping sound”) was detectable over a 6 cm diameter area between the 10th and 12th ribs in the center of the right side (Fig. 1). Ballotment in this area induced a pain reflex. However, pressure exerted just behind the xiphoid cartilage elicited no pain. No further clinical signs were exhibited by the cow i.e. the tongue sign described by DI MATTEO³ (1967) or kicks at its belly.

A firm, distended and elastic viscus could be palpated by rectal examination midway in the right anterior quadrant of the abdomen. Additionally, a firm coiled structure could be palpated in the immediate vicinity of the area of tympanitic resonance noted on auscultation.

Fluid was obtained from the distended part of the abdomen by trocarisation and cannulation under local anesthesia through a site close to linea alba and opposite to the 12th rib, using a technique described by the author (ORTOLANI⁵, 1982). Microscopic examination of the fluid (pH 3.0) collected failed to detect rumen protozoa, and the fluid was deemed to be abomasal contents. A tentative diagnosis of abomasal dilatation was made, and the cow was dosed orally with 220 ml of liquid paraffin and rehydrated with an electrolyte solution (Androsoro / Univet).

The following day, the clinical condition of the cow had deteriorated. Its rectal temperature was now 37°C and defeca-

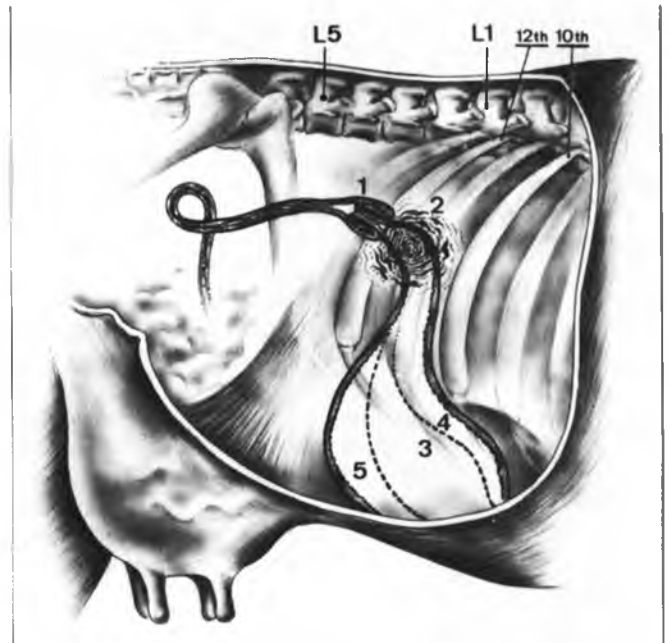


FIGURE 1

Diagrammatic representation of bovine abdomen as viewed from the right. 1 - The intussusception in the “Pars Descendens Duodeni”. 2 - Region where the tympanitic sound (ping sound) was detected. 3 - Dotted lines represent the normal topographic position of the abomasum. 4,5 - Actual position of the abomasum (at the bottom end of line 5). Place where it was punctured to collect peritoneal fluid.

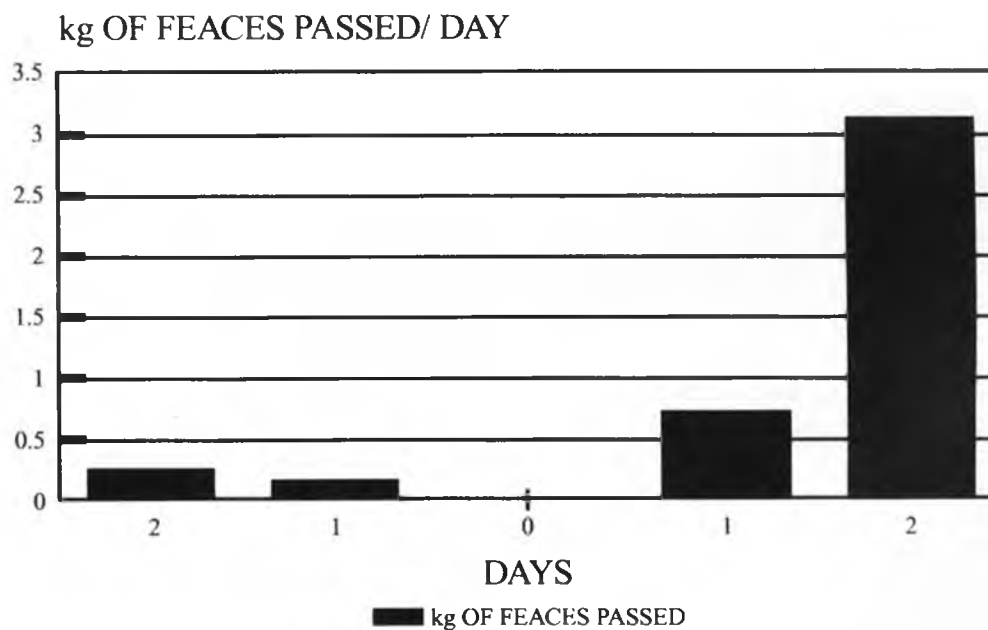


FIGURE 2

Faecal excretion before and after the surgery.

tion had ceased. So it was decided to perform an exploratory laparotomy through the right paralumbar fossa. The animal was sedated with 35 mg of xylazine (Rompun / Bayer) and a local anesthesia to block the ventral and dorsal branches of the lumbar nerves was performed by infiltration of 15 ml of a solution containing lignocaine hydrochloride (2% w/v) and adrenaline (0.00125% w/v). When the peritoneum was excised, dilated loops of intestine emerged through the opening, revealing the intussusception. Attempts at gentle manipulation caused the necrotic intestine to rupture with separation of the intussusceptens and the intussusceptum. The affected bowel was resected, and the healthy intestinal segments reunited by an "end to end" enteroanastomosis through one plane of continuous inverting suture pattern (Cushing) using a chromic catgut (number zero). The same material was used to suture the muscles layers and for the skin closure cotton thread was used.

To the cow was given 27,500,000 IU procaine benzylpenicillin G and 10 g streptomycin intramuscularly daily for 5 days. To combat shock and dehydration, 10 litres of glucose-saline were given daily intravenously.

The day after surgery, the cow was still dull and tended to lie as before, with the head turned to the flank.

The only food eaten was a little roughage. On the second day, the cow stood all the time and ate regularly. Its rectal temperature was 38.5 °C. Rumen motility was fully restored and it passed > 3 kg of pasty faeces (Fig. 2) covered by the liquid paraffin given before the surgery. One week after the surgery, the cow was returned to the farm and made an uneventful recovery.

DISCUSSION

Intussusception of the duodenum is very rare in cattle (SMITH⁹, 1984). It was impossible to determine the underlying cause of the intussusception in this cow, because no intraluminal or intramural lesion was found during surgery. The diet could not be incriminated, because the roughage eaten was not heavily fertilized, on the contrary the grass had high level of crude fibre (32%). It was not clear if anatomical, physiological or metabolic conditions contributed to the development of the aliment.

The main clinical signs presented when the cow was examined (depressed demeanour, recumbency and decreased defecation) suggested that the intussusception was well evolved. According to DI MATTEO³ (1967) there are two clinical phases in the evolution of intussusception in cattle: colic in the first 12 to 24 h followed by depressed demeanour and suppression of intestinal functions (anorexia, lack of rumination and defecation etc).

The clinical signs were compatible with the magnitude and topographic position of the intussusception. Evidently the total obstruction of the **pars descendens duodeni** (Fig.1) prevented progress of digesta through the intestines and caused dilatation and expansion of the abomasum dorsally and caudally to the observed position. This was confirmed when abomasal contents rather than peritoneal fluid were collected by trocarisation that the intestine was obstructed has confirmed by the abrupt cessation of defecation 24 h before surgical intervention.

Laparotomy made it clear that the distended viscus palpable on rectal examination was the dilated abomasum, while the coiled and firm structure was telescoped duodenum.

The circumscribed area of tympanitic resonance detected on auscultation conformed precisely to descriptions by other clinicians, SMITH et al.¹¹ (1982), investigating dilatation of the cranial segment of the duodenum. Presumably, the tympanitic resonance was due to accumulation of gas under pressure, possibly forced out of the distended abomasum into the **pars cranialis duodeni** just proximal to the intussusception (HOFFSIS; McGUIRK⁴, 1981).

Surgical intervention in this instance was so successful in restoring passage of digesta from the abomasum that it was not necessary to treat the metabolic alkalosis that normally accompanies proximal intussusception⁴.

ACKNOWLEDGMENTS

The critical review of Dr. Kenneth W. Angus (Moredun Research Institute / Edinburgh-Scotland) and suggestions of Dr. Hamiltom Silva P. Júnior are gratefully acknowledge.

RESUMO

Neste trabalho descreve-se caso clínico raro de intussuscepção no segmento "par descendi" do duodeno em vaca leiteira de 3 anos de idade. Os principais sinais clínicos evidenciados eram súbita anorexia, queda na produção leiteira, estase ruminal e parada de defecação. Pela auscultação foi detectada diminuição nos borborigmos do abomaso e dos intestinos; contudo, um som metálico foi emitido, quando de percussão-auscultatória, no flanco direito entre 10ª e 12ª costelas. No exame retal foi detectada estrutura visceral distendida, firme e elástica no quadrante anterior direito do abdome. O diagnóstico definitivo foi determinado quando da laparotomia exploratória. Em seguida à retirada dos segmentos intestinais afetados, realizou-se uma enteroanastomose. O tratamento médico consistiu de antibioticoterapia e de hidratação, por cinco dias, que precedeu a rápida recuperação clínica do animal. Discute-se neste trabalho a origem dos sinais clínicos apresentados pelo animal.

UNITERMOS: Intussuscepção; Bovinos; Tratamento

REFERENCES

- 01 - BOSSHART, J.K. Telescoped intussusception in cattle. *Cornell Veterinarian*, v.20, n.1, p.55-8, 1930.
- 02 - DERIVAUX, J.; DEWALQUE, J. Invagination intestinale chez une vache. Guérison après entérectomie. *Annales de Médecine Vétérinaire*, v.103, n.4, p.256-67, 1959.
- 03 - DI MATEO, P. Un sintomo caratteristico per una tempestiva esatta diagnosi di invaginamento intestinale e di cambiamento di posizione dell'intestino nei bovini (segno della lingua). *Atti della Società Italiana delle Scienze Veterinarie*, v.21, p.563-5, 1967.
- 04 - HOFFSIS, G.F.; McGUIRK, S.M. Diseases of the abomasum and intestinal tract. In: HOWARD, J.L. *Current veterinary therapy*. Food animal practice. Philadelphia, W.B. Saunders, 1981, p.891-910.
- 05 - ORTOLANI, E.L. Determinação das características físico-químicas e citológicas do líquido peritoneal de bovinos normais. In: SEMANA DE VETERINÁRIA. 1. São Paulo, 1982. *Resumos*. São Paulo, Faculdade de Medicina Veterinária e Zootecnia, 1982. p.79.
- 06 - PEARSON, H. Intussusception in cattle. *Veterinary Record*, v.89, n.16, p.426-37, 1971.
- 07 - PUGET, E.; CAZIEUX, A. Bowel resection in the bovine. *Modern Veterinary Practice*, v.41, n.19, p.34-7, 1960.
- 08 - ROBERTSON, J.T. Differential diagnosis and surgical management of intestinal obstruction in cattle. *Veterinary Clinics of North American. Food Animal Practice*, v.1, n.2, p.377-94, 1979.
- 09 - SMITH, D.F. Bovine intestinal surgery. Part 3. *Modern Veterinary Practice*. v.65, p.909-14, 1984.
- 10 - SMITH, D.F. Bovine intestinal surgery. Part 6. *Modern Veterinary Practice*, v.66, p.443-6, 1985.
- 11 - SMITH, D.F.; ERB, H.N.; KALAHAR, K.M.; REBHUN, W.C. The identification of structures and conditions responsible of right side tympanitic resonance (ping) in adult cattle. *Cornell Veterinarian*, v.72, p.180-99, 1982.

Recebido para publicação em 27/01/94
Aprovado para publicação em 07/11/94