

Laparoscopic treatment of giant circumferential leiomyoma of the distal esophagus: case report

Tratamento laparoscópico de leiomioma gigante circunferencial de esôfago distal: relato de caso

Luana Cabrino Aranha¹, Nilton César Aranha², André Brandalise³, Nelson Ary Brandalise⁴

Aranha LC, Aranha NC, Brandalise A, Brandalise NA. Laparoscopic treatment of giant circumferential leiomyoma of the distal esophagus: case report / *Tratamento laparoscópico de leiomioma gigante circunferencial de esôfago distal: relato de caso*. Rev Med (São Paulo). 2020 Jan-Feb;99(1):84-7.

ABSTRACT: *Introduction:* Leiomyomas are rare esophagus tumors, with 0.4-1% incidence of all esophagus tumors. Only 5% grow to the point of being called giant tumors, measuring more than 10cm. Symptoms usually begin on tumors bigger than 5cm. *Objective:* Reporting a new therapeutic course of action to giant leiomyomas of distal esophagus. *Case Report:* VCA, female, 38 years old, presented retrosternal oppression for 4 months. Having realized a computed tomography on another service which demonstrated a mass suggestive of leiomyoma. On the endoscopy exam, performed for heartburn complaint and mild dysphagia, was determined a hiatal hernia of 2cm and mild gastritis. Patient submitted to complete excision of tumor without mucosal lesion and reconstruction of the external muscular wall, by the video laparoscopic method. Hiatoptasty and partial esophagogastrifundoplication were associated. The anatomic pathological examination confirmed leiomyoma, with 10x5x2cm. Patient evolved clinically without the appearance of the heartburn or dysphagia. With contrast examination of the esophagus after 6 months and endoscopy and tomography the following 4 years, all normal. The classic treatment of giant leiomyomas, includes thoracotomy with esophagectomy. Considering that in 80% of the cases it is found in the middle and lower thirds of the esophagus, the videolaparoscopic approach by transhiatal route becomes possible. The reconstruction of the external muscular layer is important to prevent a possible prolapse of the mucosa. Also, the realization of the fundoplication in addition to avoiding the gastroesophageal reflux, allows the suture area of the esophageal muscular wall to be covered, increasing the safety in the treatment. In services with experience in the surgical treatment of diseases of the gastric esophagus transition through the videolaparoscopic method, it is possible to perform with adequate safety the surgical treatment of the tumor lesions of the distal esophagus. The method provides greater postoperative comfort and prompt clinical surgical recovery.

Keywords: Leiomyoma/surgery; Esophagus; Neoplasms/diagnosis; Laparoscopy; Surgery, computer assisted.

RESUMO: *Introdução:* O leiomioma é um tumor de esôfago raro, com incidência de 0,4-1% dos tumores de esôfago. Apenas 5% crescem a ponto de serem denominados gigantes, maiores do que 10 cm. Sintomas costumam surgir nos tumores iguais ou maiores que 5 cm. *Objetivo:* Relatar um novo curso de ação terapêutica para leiomiomas gigantes do esôfago distal. *Caso Clínico:* VCA, sexo feminino, 38 anos, apresentava há 4 meses sensação de opressão retroesternal. Realizou tomografia computadorizada(CT) em outro serviço demonstrando lesão de esôfago distal sugestivo de leiomioma. No exame de endoscopia, realizado por queixa de azia e leve disfagia, foi determinado hiato alargado em 2cm e gastrite leve. Paciente submetida a exérese de lesão tumoral íntegra sem lesão mucosa e reconstrução da parede muscular externa, pelo método videolaparoscópico. Associou-se hiatoptastia e esofagogastrifunduplicatura parcial. O exame anátomo patológico confirmou o leiomioma, com 10x5x2cm. *Evolução:* Evoluiu clinicamente a longo prazo sem o aparecimento de azia ou disfagia. Submetida a exame contrastado do esôfago após 6 meses, tomografia e endoscopias de controle pelos próximos 4 anos, todos normais. *Discussão:* O tratamento clássico do leiomioma gigante inclui toracotomia com esofagectomia. Considerando que em 80% dos casos a lesão se encontra nos terços médio e inferior do esôfago, a abordagem videolaparoscópica por via transhiatal se torna possível. A reconstrução da muscular externa é importante para prevenir um possível prolapso da mucosa. A realização da funduplicatura além de evitar o refluxo gastroesofágico, possibilita que a área de sutura da parede muscular do esôfago seja recoberta, aumentando a segurança no tratamento. *Comentários Finais:* Em serviços com experiência na realização de tratamento cirúrgico das doenças da transição esôfago gástrica pelo método videolaparoscópico, é possível realizar tal o tratamento cirúrgico com adequada segurança. O método proporciona ao paciente um maior conforto pós operatório e pronta recuperação clínico cirúrgica.

Descritores: Leiomioma/cirurgia; Esôfago; Neoplasias/diagnóstico; Laparoscopia; Cirurgia assistida por computador.

Trabalho realizado no: Centro Médico de Campinas. Apresentado no XXXVIII Congresso Médico Universitário da FMUSP – COMU, 2019 - 1st. Place of the Panels Awards - Report Case in the Scientific Awards COMU 2019.

1. Pontifícia Universidade Católica de Campinas. <https://orcid.org/0000-0001-9023-8116>. Email: luana.c.aranha@gmail.com.

2. Orientador. Cirurgião do Aparelho Digestivo e Obesidade Mórbida do Hospital Fundação. Centro Médico Campinas (FCMC). Assistente Estrangeiro da Universidade Louis Pasteur – Strasbourg – França. <https://orcid.org/0000-0001-7568-5241>. Email: aranha@gastrosite.com.br.

3. Cirurgião do Aparelho Digestivo. Titular e Presidente SOBRACIL - Capítulo São Paulo (2018-2019). <https://orcid.org/0000-0002-0285-2122>. Email: andre@gastrosite.com.br.

4. Cirurgião do Aparelho Digestivo. Chefe Fundador do Serviço de Endoscopia do Hospital Fundação Centro Médico Campinas. <https://orcid.org/0000-0002-6817-4475>. Email: nelsonbrandalise@hotmail.com.

Correspondence: Luana Cabrino Aranha. Rua Severo Penteado, 77. Campinas, São Paulo. CEP: 13025-050. Email: Luana.c.aranha@gmail.com.

INTRODUCTION

Leiomyoma is a rare esophageal tumor, with an incidence of 0.4-1% of esophageal tumors, but it is the most common benign tumor of this site, accounting for 67 to 80% of the cases. They are more frequent in the middle and distal esophagus and, in most cases, they are single lesions, ranging in size from 1 to 29 centimeters of diameter¹⁻³.

They occur most frequently from 20 to 69 years old, with a peak incidence in the fifth decade, being more common in men. About half of the tumors are smaller than 5 cm and only 5% of these tumors grow to the point of being called giants, with diameters larger than 10 cm⁴.

Asymptomatic in most cases, the onset of dysphagia, odynophagia, retrosternal pain and bleeding usually appear in tumors equal to or larger than 5 cm. These symptoms are usually due to compression, esophageal obstruction or cardia dysfunction.

Endoscopic biopsy is indicated in cases of ulcerated mucosa and suspected cancer⁵. Endoscopic ultrasound is considered the most specific method for diagnosing leiomyoma, assessing tumor depth and location⁶. Computed tomography determines size and relationship to neighboring organs and can also be used for periodic follow-up of incidentalomas, as this is a slow-growing benign tumor⁷.

MATERIAL AND METHODS

Through the case reported it is possible to demonstrate the possibility of performing surgical treatment of circumferential tumors of the distal esophagus using the transhiatal access with videolaparoscopic method. Thus, obtaining a postoperative period with low pain index and rapid physical recovery.

RESULTS

VCA, female, 38 years, reports having performed a computed tomography (CT) scan in another service 5 days ago for a complaint of pain in the posterior right back for one week. Presenting also chest pain and feeling of retrosternal oppression for 4 months. CT results showed nonspecific lobulated parietal thickening in the distal esophagus of submucosal origin and suggestive of leiomyoma. On examination, there were 3 cm of parietal thickness, 6.9 cm in the largest axial axis and 5.3 cm in length (Figure 1).

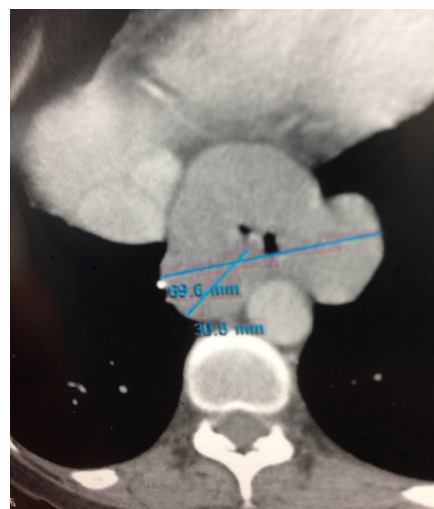

Figure 1. Computed tomography

Patient with history of ankylosing spondylitis since 19 years old and 1.5 years ago has restarted the use of medication. Four months ago underwent endoscopy at the request of a rheumatologist, for complaint of heartburn, mild dysphagia, and a feeling of stopping of the drug in the esophagus (sulfasalazine). A widened gap of two centimeters and mild gastritis were determined.

Due to the diagnosis of large and circumferential leiomyoma in the distal esophagus, laboratory tests and preoperative cardiac evaluation were performed to undergo surgical treatment. The hypothesis considered was of laparoscopic transhiatal tumor removal due to its location and, if necessary, partial esophagogastrectomy with transmediastinal gastric tube reconstruction.

Patient underwent complete excision of tumoral lesion without mucosal lesion and with preservation of vagus nerves, by the videolaparoscopic method (Figure 2). Reconstruction of the external muscular wall was performed by continuous suture with the presence of a 32-oro-gastric Fouchet tube to avoid esophageal lumen constriction. It was also complemented by a 7 cm long hiato-plasty and partial esophagogastrunduplication covering the entire esophageal area from which the lesion was resected (Figure 3).

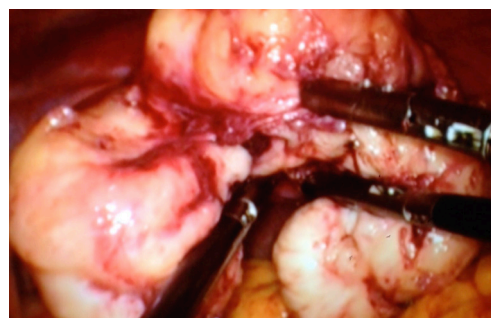


Figure 2. Resected tumor

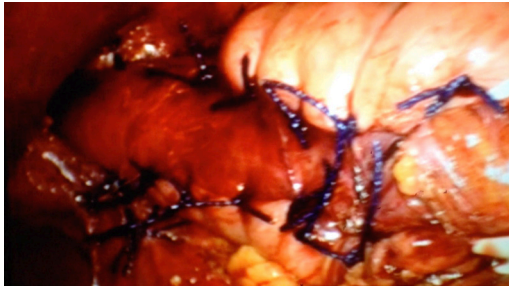


Figure 3. Hytoplasty and partial fundoplication

Patient remained in the hospital for two days, with little pain, being discharged with good acceptance of the liquid diet. (Figure 4) Postoperative care similar was maintained similar to a fundoplication, with progressive increase of food texture over the next 4 weeks.

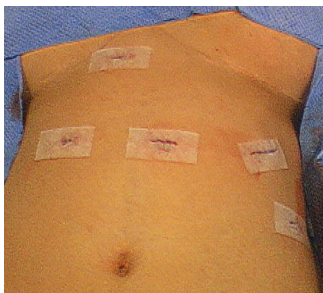


Figure 4. Immediate postoperative period

Pathological anatomical exam confirmed esophagus leiomyoma of 10 x 5.0 x 2.0 cm. Described as a proliferating neoplasm of spindle-shaped cells with elongated nuclei without atypias, arranged in bundles in various directions and containing numerous capillaries without atypias in endothelial cells.

Patient progressed clinically over the long term without the onset of heartburn or dysphagia. Also underwent control by contrast esophageal examination 6 months after surgery, without esophageal constriction and absence of reflux. Followed up by control exams such as endoscopy and tomography for the next 4 years, all normal.

DISCUSSION

The main indication for surgical removal of esophageal leiomyoma is the onset of symptoms. The most prevalent are dysphagia, odynophagia, retrosternal pain and bleeding. In the reported case, the patient presented mild dysphagia and retrosternal pain for 4 months. Surgical treatment is also indicated when there is doubt about the nature of the lesion or in cases where the lesion exceeds five centimeters⁸.

When the leiomyoma is smaller than five centimeters and asymptomatic, expectant management should be performed and follow-up with imaging and periodic

endoscopy. This is only possible considering that the esophageal leiomyoma has a characteristic radiological aspect, slow growth rate and very low risk of malignant degeneration⁸. Tomography determines the size and relationship with neighboring organs, and can also be used for periodic follow-up of incidentalomas as this is a slow growing benign tumor⁷.

Often the lesion is discovered as an endoscopic examination finding, incidentaloma. Complementary radiological exams are: contrast esophageal examination, computed tomography and endoscopic US. Because it is a submucosal lesion, endoscopic biopsy for attempted histological diagnosis is often inconclusive because adequate material is not available. Biopsy is indicated only in cases where ulceration is present and muscle tissue is exposed. In the case in question, the mucosa was intact and it was decided not to perform a biopsy attempt⁹.

In particular, considering that its performance may generate adhesions of the mucosa to the tumor, making it difficult to enucleate without mucosal injury during surgery^{1,8}.

Endoscopic US is considered the most specific method for diagnosing leiomyoma⁶. This test was not performed because the CT clearly described the origin of the lesion in the mucosal muscle and the high probability of benign disease was discussed with the radiologist¹.

Considering the very low probability of it being a malignant lesion, the surgical team was prepared for a possible partial esophagogastrectomy with transmediastinal gastric tube reconstruction given the extent and esophageal involvement of the lesion. It was not necessary to perform it either because of the characteristics found, also because the execution of external muscle reconstruction was possible.

Of the esophageal leiomyomas, about half of them are smaller than 5 cm and only 5% are larger than 10 cm⁴. Those larger than 10 cm are called giant leiomyomas. The classic treatment of giant leiomyoma includes esophagectomy thoracotomy and esophagogastrostomy. Thoracotomy significantly increases morbidity, with greater respiratory complications, longer time for diet reintroduction, greater surgical trauma, and anastomosis-related complications, which increase hospitalization time and worsens the prognosis³. With the advances in minimally invasive surgery, there are already some cases of thoracoscopic treatment described.

The first extramucosal enucleation of an esophageal leiomyoma was described by Ohsawa in 1933 and has since been the approach of choice. In 1992, the first publication of videothoracoscopy enucleation took place¹.

Considering that in 80% of cases the esophageal leiomyoma is found in the middle and lower thirds of the esophagus, the transhiatal videolaparoscopic approach becomes possible⁸.

In the case described, the transhiatal approach also made it possible to correct the gap widening of the patient

in question. In addition, dissection of the esophagogastric transition favors gastroesophageal reflux after surgery. Therefore, fundoplication allows the suture area of the esophageal muscle wall to be covered, thus increasing the safety in surgical treatment and avoiding the possibility of postoperative gastroesophageal reflux¹⁰.

Enucleation in the case of giant tumors becomes inappropriate due to the extensive defect in myotomy, evolving to mucosal diverticula or dysphagia. Most cases are treated with esophagectomy and reconstruction with the colon, but there are cases of treatment with enucleation and correction of the muscle defect with a large omentum flap, but performed by thoracotomy⁴.

There is a case in the described literature of a 22.5 x 10 x 7.5 cm leiomyoma treated by enucleation. There was mucosal perforation, but it was not necessary to convert the surgery, the correction was made with absorbable stitches and it was verified that there were no endoscopic leaks⁴.

There is also a case in the literature, where a 10 cm leiomyoma was enucleated by a 2cm myotomy using robotic assisted thoracoscopy. Robotic assisted thoracoscopy reduced mucosal lesions from 15% to 1%¹¹.

The choice of method depends on several factors: a) The esophageal leiomyoma is so large that resection without mucosal damage is impossible; b) Adherence between leiomyoma and esophageal mucosa is strong and extensive; (c) irreparable mucosal defect caused by resection; d) Giant leiomyoma in distal esophagus and extending through the

cardia; e) Suspected Leiomyosarcoma.

In the case described, enucleation of a circumferential giant tumor was performed by transhiatal videolaparoscopy. Because it originated from the mucosa muscle, it was possible to open the external muscle, completely resect the lesion without damaging the mucosa, followed by reconstruction of the external muscle by continuous suture with Vicryl 3.0 thread. Care was taken to maintain a 32 Fouchet probe during the procedure to avoid esophageal constriction in the lesion area. Reconstruction of the external muscle is important to prevent possible mucosal prolapse. In particular, the fundoplication performed on the suture area is also able to protect in a complementary manner, preventing prolapse and preventing postoperative gastroesophageal reflux.

CONCLUSION

In services with adequate experience in the surgical treatment of gastric esophageal transition diseases by videolaparoscopic method, it is possible to safely perform the surgical treatment of tumoral lesions of the distal esophagus. The transhiatal approach makes it possible to exert even giant and circumferential leiomyomas from this region. The method provides the patient with greater postoperative comfort and prompt clinical surgical recovery.

REFERENCES

1. Loviscek LF, Yun JH, Park YS, Chiari A, Grillo C, Cenoz MC. Leiomyoma of the oesophagus. *Cir Esp*. 2009;85(3):147-51. doi: <http://dx.doi.org/10.1016/j.ciresp.2008.09.004>.
2. Karagülle E, Akkaya D, Türk E, Göktürk HS, Yildirim E, Moray G. Giant leiomyoma of the esophagus: a case report and review of the literature. *Turk J Gastroenterol*. 2008;19(3):180-3. Available from: <https://www.turkjgastroenterol.org/en/giant-leiomyoma-of-the-esophagus-a-case-report-and-review-of-the-literature-1621391>.
3. Hu X, Lee H. Complete thoracoscopic enucleation of giant leiomyoma of the esophagus: a case report and review of the literature. *J Cardiothorac Surg*. 2014;14(9):34. doi: <http://dx.doi.org/10.1186/1749-8090-9-34>.
4. Cheng BC, Chang S, Mao ZF, Li MJ, Huang J, Wang ZW, Wang TS. Surgical treatment of giant esophageal leiomyoma. *World J Gastroenterol*. 2005;11(27):4258-60. doi: <http://dx.doi.org/10.3748/wjg.v11.i27.4258>.
5. Punpale A, Rangole A, Bhambhani N, Karimundackal G, Desai N, Ashwin de Souza. Leiomyoma of esophagus. *Ann Thorac Cardiovasc Surg*. 2007;13:78-81.
6. Xu GQ, Zhang BL, Li YM, Chen LH, Ji F, Chen WX. Diagnostic value of endoscopic ultrasonography for gastrointestinal leiomyoma. *World J Gastroenterol*. 2003;9:2088-91. doi: <http://dx.doi.org/10.3748/wjg.v9.i9.2088>.
7. Rice TW. Benign esophageal tumors: esophagoscopy and endoscopic esophageal ultrasound. *Semin Thorac Cardiovasc Surg*. 2003;15:20-26. doi: [10.1016/s1043-0679\(03\)00035-2](http://dx.doi.org/10.1016/s1043-0679(03)00035-2).
8. Pereira FB, Leão B, Leli LF, Lima MPL. Leiomioma de esôfago com características epidemiológicas anormais: relato de caso. *Rev Med (São Paulo)*. 2018;97(3):357-60. doi: <http://dx.doi.org/10.11606/issn.1679-9836.v97i3p00-00>.
9. Albuquerque W, Rocha LCM, Faria KB. Tumores benignos de esôfago. In: SOBED Sociedade Brasileira de Endoscopia Digestiva. *Endoscopia diagnóstica e terapêutica*. São Paulo; data? Cap.28, p.219 [citado 2 mar. 2019]. Disponível em: http://www.gastrointestinalmed.com.br/downloads/Tumores_Benignos_esofago.pdf.
10. Marmuse JP, Johanet H, Louvent F, Benhamou G. Leiomyomas of the lower third of the esophagus. Value of transhiatal enucleation. *Ann Chir*. 1994;48:446-51.
11. Compean SD, Gaur P, Kim MP. Robot assisted thoracoscopic resection of giant esophageal leiomyoma. *Int J Surg Case Rep*. 2014;5(12):1132-4. doi: <http://dx.doi.org/10.1016/j.ijscr.2014.11.003>.

Received: November 06, 2019

Accepted: November 08, 2019