

## Lemierre's syndrome due to intratumoral abscess of the uvula

Hassan Rahhal<sup>a</sup>, Fernando Peixoto Ferraz de Campos<sup>b</sup>, Cristiane Rubia Ferreira<sup>c</sup>,  
Aloisio Felipe-Silva<sup>c</sup>

Rahhal H, Campos FPF, Ferreira CR, Felipe-Silva A. Lemierre's syndrome due to intratumoral abscess of the uvula. *Autopsy Case Rep* [Internet]. 2015;5(3):11-20. <http://dx.doi.org/10.4322/acr.2015.015>

### ABSTRACT

Lemierre's syndrome (LS), described in detail in 1936, used to be a life-threatening entity until the advent of antibiotics. Tonsillitis or pharyngitis are the main primary infections and oropharyngeal anaerobic flora is the predominant etiology. However, other primary site infections, as well as other microbiological agents have been reported since the first description. Inflammatory symptoms in the neck and marked findings on physical examination predominate the majority of cases. Nonetheless, the authors report the case of a 54-year-old man with a history of dysphagia followed by cough, purulent expectoration, and fever. The bad condition of his dentition was noteworthy. During the diagnostic work-up, an ulcerated lesion in the uvula and a middle lobe pneumonia were disclosed. *Streptococcus viridans* was isolated from blood culture. On the fifth day of hospitalization, the patient died after a copious episode of hemoptysis. The autopsy findings depicted an abscess within a squamous cell carcinoma of the uvula, pharyngitis with carotid sheath spreading accompanied by pyelphlebitis and thrombosis of the internal jugular vein up to the innominate vein, surrounded by an abscess in the mediastinum. Alveolar hemorrhage and pneumonia were also present. We conclude that the ulcerated carcinoma of the uvula housed an abscess, facilitated by the poor oral hygiene, which triggered LS and the descending mediastinitis. Pulmonary involvement was due to the septic embolism from the internal jugular vein. We would like to highlight the uvula abscess as the primary site of infection in this case of LS with *S. viridans* as the causative agent.

### Keywords

Mediastinitis; Hemoptysis; Phlebitis; Uvula; Viridans streptococci; Sepsis; Autopsy

### CASE REPORT

A 54-year-old male patient sought medical care complaining of a 2-week history of dysphagia (mainly for solids) followed by dyspnea, coughing with purulent sputum, fever, and non-quantified weight loss. He had a history of tobacco smoking (40 packs per year) and alcoholic abuse until 4 years ago. He denied any comorbidity and use of medication. The physical examination showed an ill-looking patient, presenting

tachypnea. His blood pressure was 88/48 mmHg; pulse rate was 142 beats per minute; respiratory frequency was 36 respiratory movements per minute; axillary temperature was 38.2 °C; and room air oximetry was 85%. His teeth were direly preserved. Pulmonary auscultation revealed rales in lung bases. Cardiac, abdominal, and limbs examination was normal. The patient was admitted with the diagnosis of sepsis

<sup>a</sup> Department of Internal Medicine - Hospital das Clínicas - University of São Paulo, São Paulo/SP – Brazil.

<sup>b</sup> Internal Medicine Division - Hospital Universitário - University of São Paulo, São Paulo/SP – Brazil.

<sup>c</sup> Anatomy Pathology Service - Hospital Universitário - University of São Paulo, São Paulo/SP – Brazil.



of pulmonary origin; therefore, he was prescribed volume resuscitation with crystalloids, ceftriaxone plus clindamycin, and oxygen supplementation. The outcome was favorable with normalization of the hemodynamic parameters and oximetry improvement. However, fever and tachypnea persisted. Initial laboratory examinations are shown in Table 1.

The upper digestive endoscopy revealed an ulcerated uvula lesion (Figure 1) and mild erosive gastritis.

Chest plain radiography showed anterior mediastinum enlargement and airspace-filling opacity

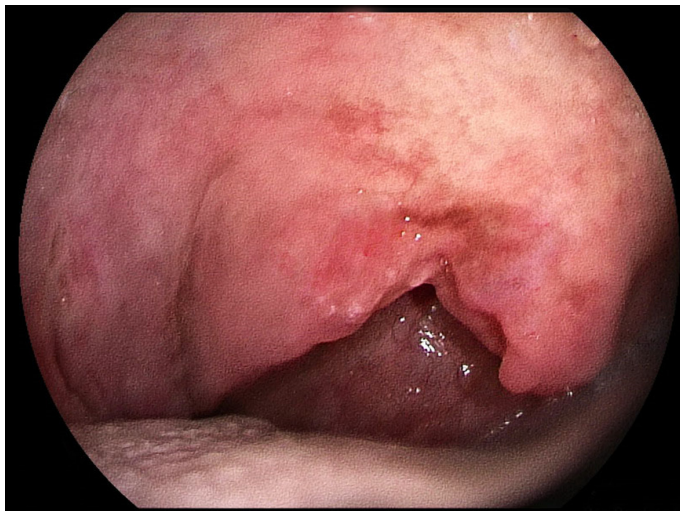
blurring the right cardiac silhouette, consistent with middle lobe pneumonia (Figure 2).

Although the patient's clinical status improved, oxygen supplementation was continuously required, and the fever and tachypnea did not cease. On the fifth day of hospitalization, the patient suddenly presented a marked bleeding exteriorized via the mouth. A cough with bloody sputum was followed by loss of consciousness; then, soon after, the patient presented cardiac arrest, which did not positively respond to the advanced cardiac life support maneuvers. An autopsy was subsequently performed.

### AUTOPSY FINDINGS

Samples of the oropharynx and the uvula were examined. The histologic examination showed an invasive ulcerated squamous carcinoma of the malpighian mucosa of the uvula surrounded by acute inflammatory process (Figure 3).

Cross- and sequential cuts of the neck region up to the mediastinum (involving the carotid sinus route) revealed left internal jugular vein thrombosis, which extended to the left innominate vein (brachiocephalic vein), and circumjacent friable tissue. The microscopic examination revealed an acute inflammatory infiltration and a micro abscess in the peritonsillar region, which involved the whole carotid sheath with thrombophlebitis of the left internal jugular vein up to the left innominate vein, as well as the rupture of the

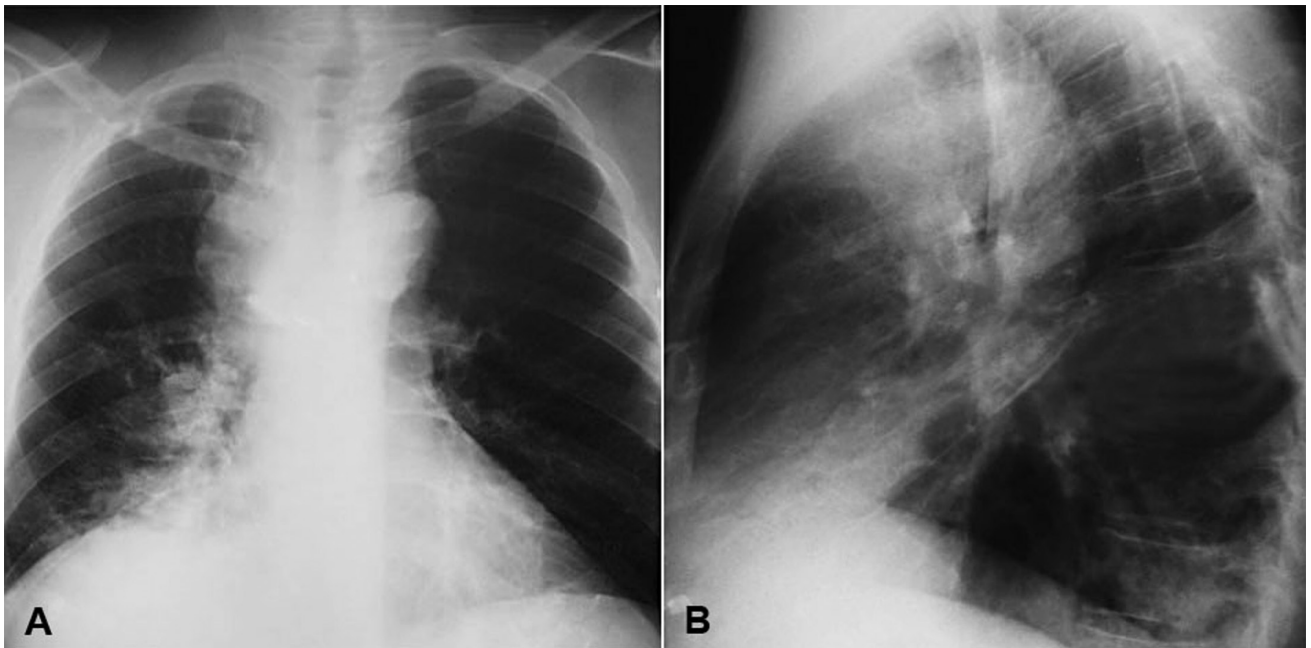


**Figure 1.** Endoscopic view of the soft palate showing edema plus a destructive and infiltrative lesion of the uvula.

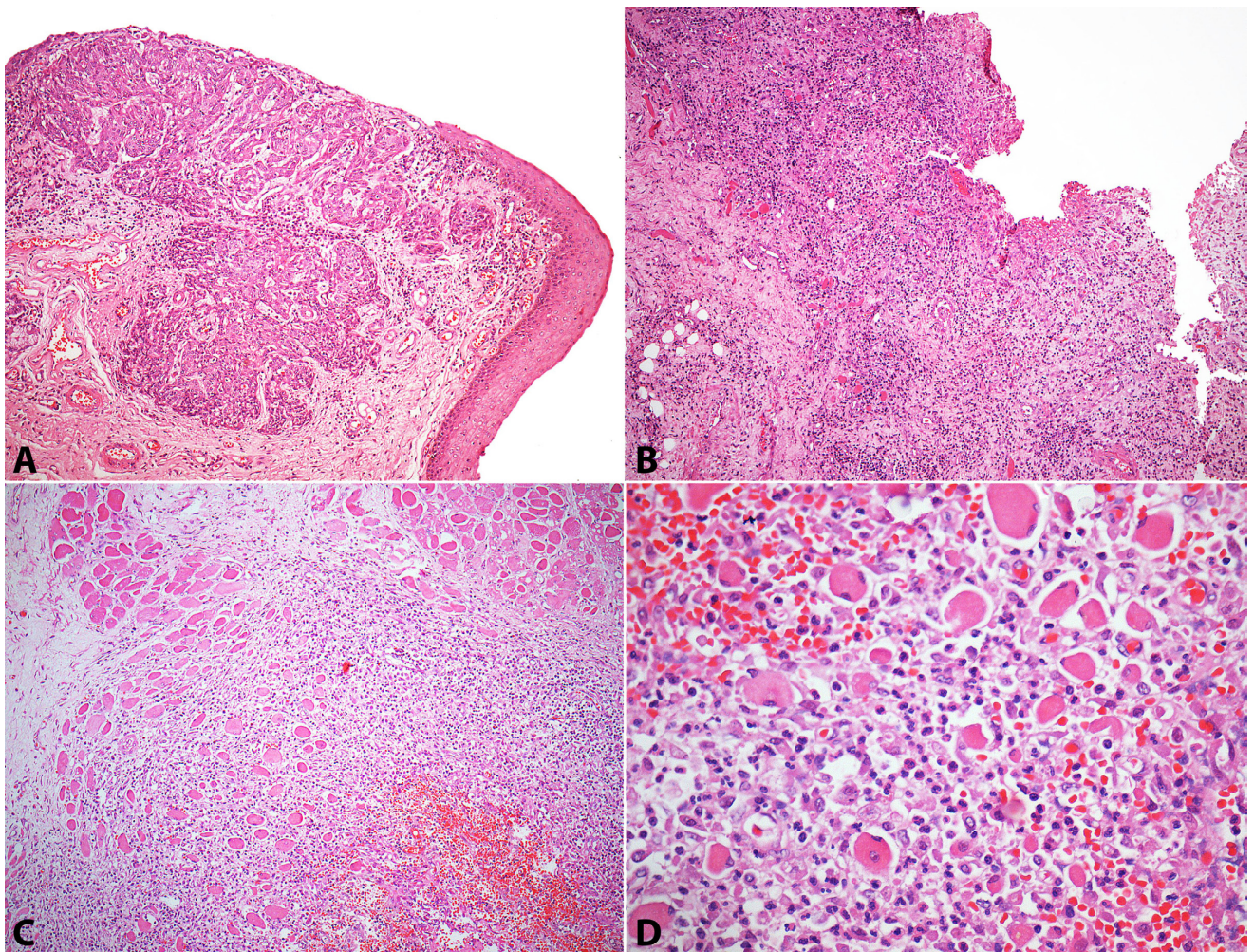
**Table 1.** Initial laboratory work-up

		RV			RV
Hemoglobin	12.1	12.3-15.3 g/dL	Urea	73	5-25 mg/dL
Hematocrit	36.9	36.0-45.0%	Creatinine	0.81	0.4-1.3 mg/dL
Leukocytes	23.9	4.4-11.3 × 10 <sup>3</sup> /mm <sup>3</sup>	Potassium	4	3.5-5.0 mEq/L
Bands	17	1-5%	Sodium	137	136-146 mEq/L
Segmented	76	45-70%	ALT	58	9-36 U/L
Eosinophils	0	1-4%	AST	99	10-31 U/L
Basophils	0	0-2.5%	AF	124	53-128 U/L
Lymphocytes	3	18-40%	γGT	82	2-30 U/L
Monocytes	4	2-9%	TP/Albumin	7.1/3.3	6.4-8.3/3.5-5.2 g/dL
Platelets	266	150-400 × 10 <sup>3</sup> /mm <sup>3</sup>	Lactate	13.3	
INR	1.09	1.0	Glucose	134	<99 mg/dL

AF = alkaline phosphatase; ALT = alanine aminotransferase; AST = aspartate aminotransferase; γGT = gamma-glutamyl transpeptidase; INR = international normalized ratio; RV = reference value; TP = total protein.



**Figure 2.** Chest plain radiography, **A** – PA frontal view, **B** – lateral view; showing airspace filling opacity in the middle and inferior lobes, as well as anterior mediastinum enlargement.



**Figure 3.** Photomicrography of the uvula and parapharyngeal tissue. **A** – Invasive squamous cell carcinoma of the malpighian mucosa of the uvula (HE, 100X); **B** – Ulcerated lesion and acute inflammatory infiltrate within the uvula (HE, 100X); **C** – Microabscess in the parapharyngeal soft tissue (HE, 100X); **D** – Detail of the flegmonous acute inflammatory process infiltrating the parapharyngeal soft tissue (HE, 400X).

latter in continuity with the mediastinal abscess, where Gram-positive cocci colonies were found (Figure 4 and Figure 5).

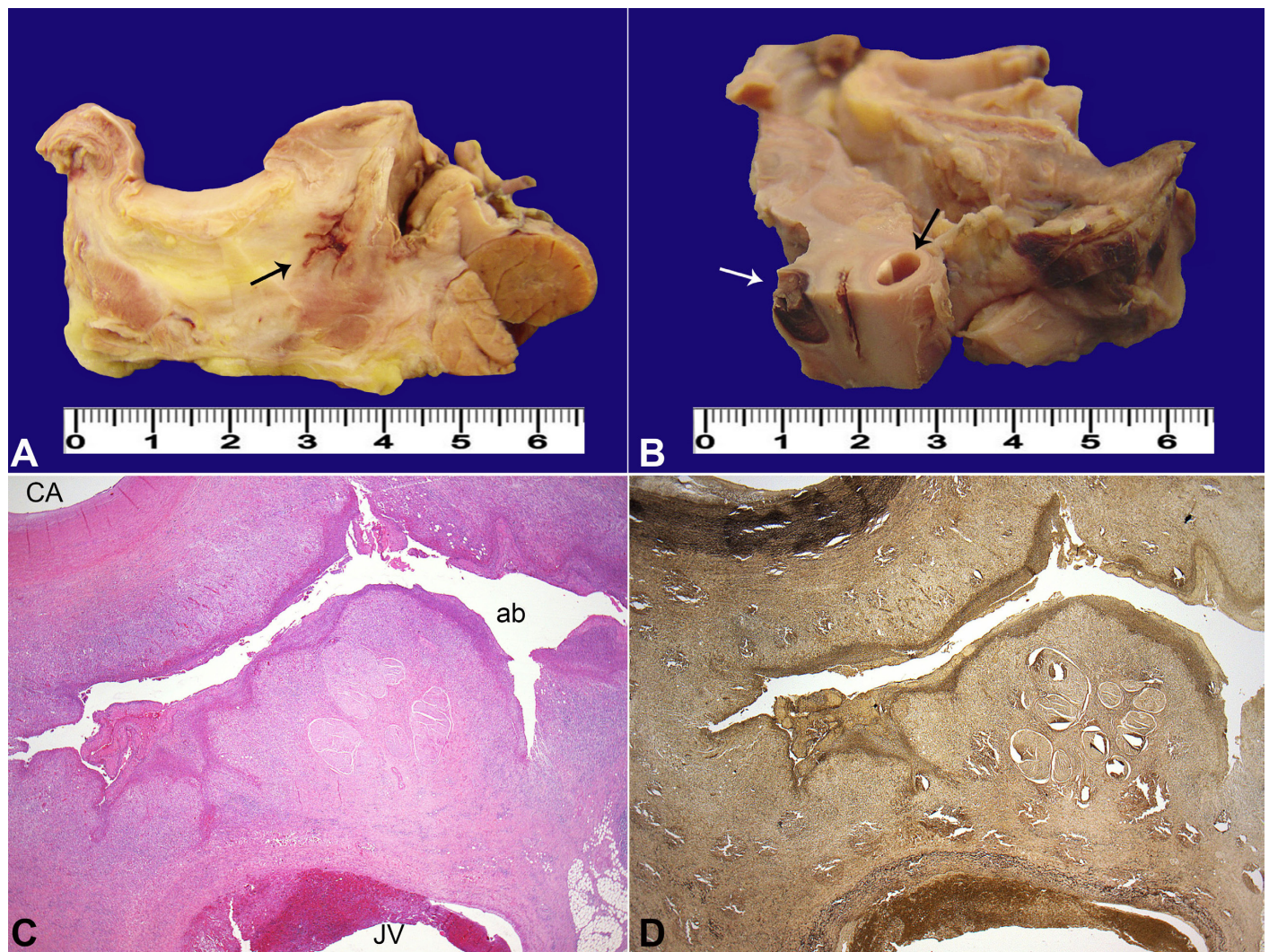
At the respiratory and digestive tract overture, blood clots at the carina and within the stomach (Figure 6) were found, without any evidence of ulcer or erosions of the gastric mucosa.

Both lungs were heavy, congested, and exhibited pleural adhesions (right lung weight = 836 g (mean reference value [mRV]: 450 g; left lung weight = 490 g [mRV: 375 g]). At the cut surface they were purplish with friable areas, and blood clots filled the bronchial tree. At microscopy, the pulmonary parenchyma showed extensive areas of alveolar hemorrhage

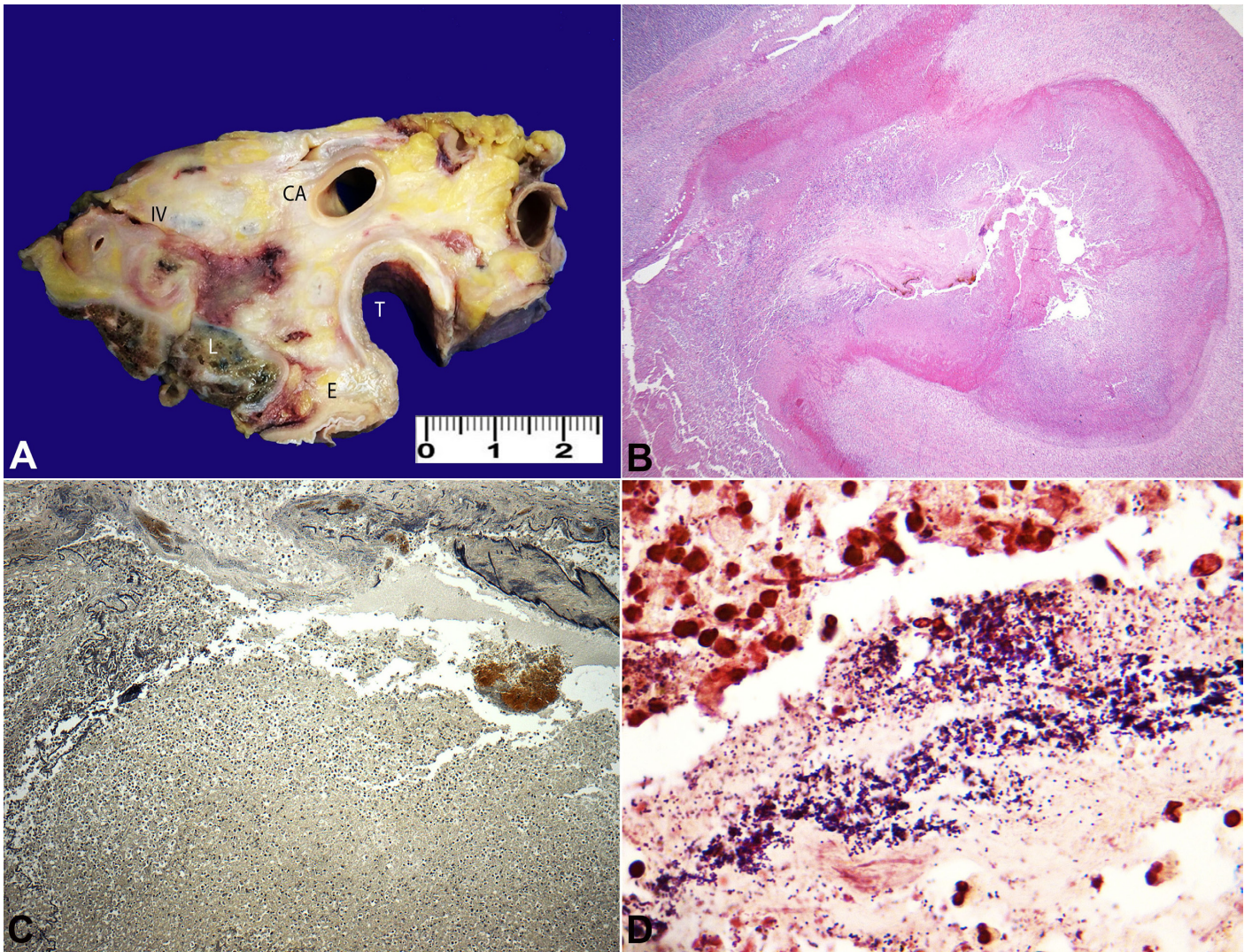
and pneumonia besides foci of diffuse alveolar damage and alveolar edema, as well as a small area of pulmonary infarction (Figure 7). After thorough investigation, neither fistula from the mediastinum lesion to the pulmonary parenchyma, nor septic thrombosis to lungs, were found.

Other findings related to septic shock were: hepatic parenchyma (liver weight = 2004 g [RV; 1500 g]) showing mild sinusoidal dilation, neutrophilic infiltration of the portal triad and sinusoids, focal lobular hepatocyte necrosis, ductular cholestasis, and grade 2 siderosis (Figure 8).

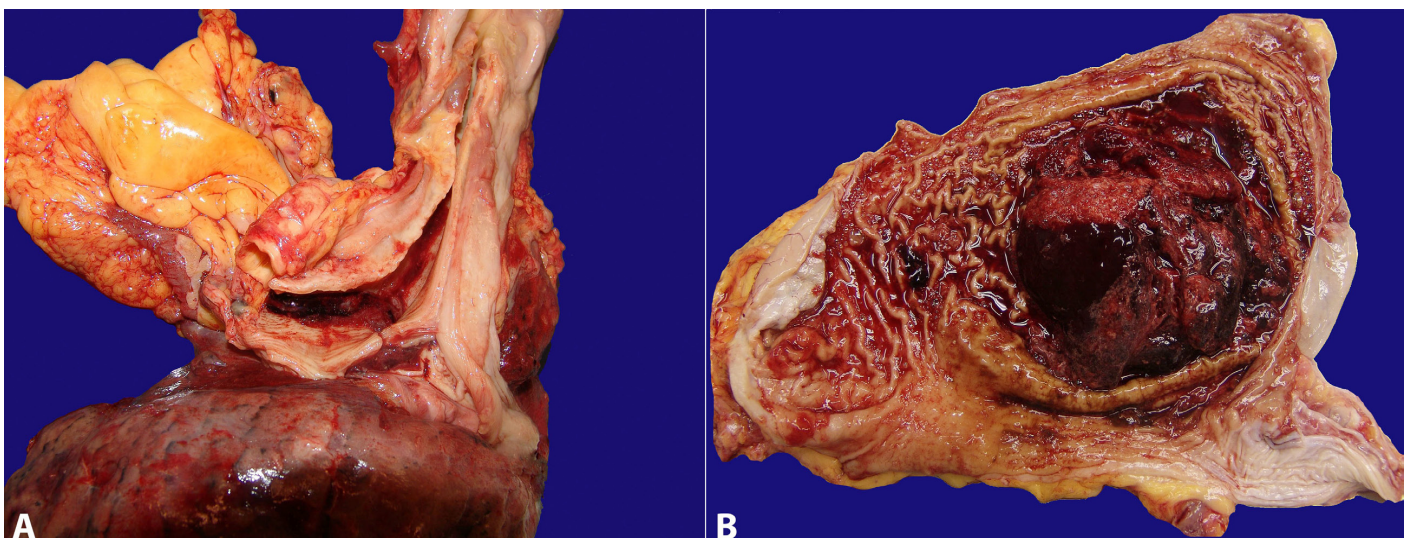
The spleen weighed 269 g (RV: 112 g) and showed acute splenitis and red pulp congestion. The kidneys



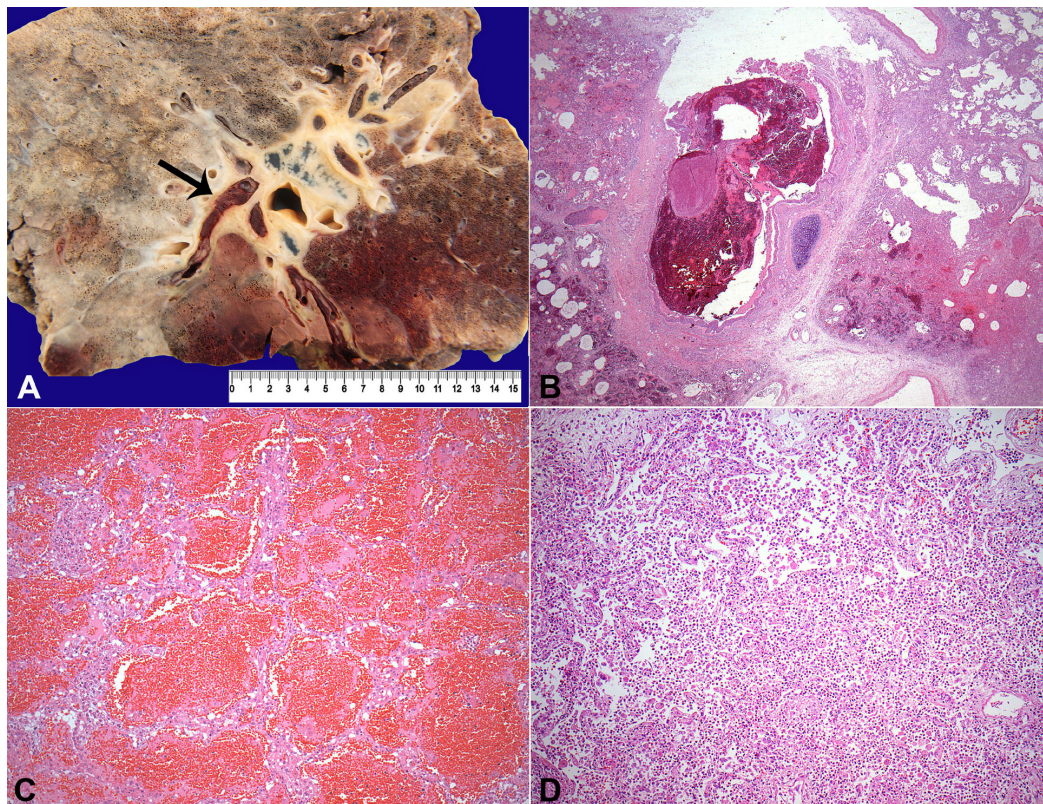
**Figure 4.** **A** – Gross finding of the cross section of the cervical tissue showing an abscess in the high parapharyngeal region (black arrow); **B** – Cross section of the carotid sheath with internal jugular vein thrombosis (white arrow) and a friable tissue between the vessels (carotid artery; black arrow); **C** – Panoramic photomicrography showing the abscess (ab) between the carotid artery (CA) and the thrombosed internal jugular vein (JV) (HE, 25X); **D** – Verhoff staining of the slice showed in **C** (25X).



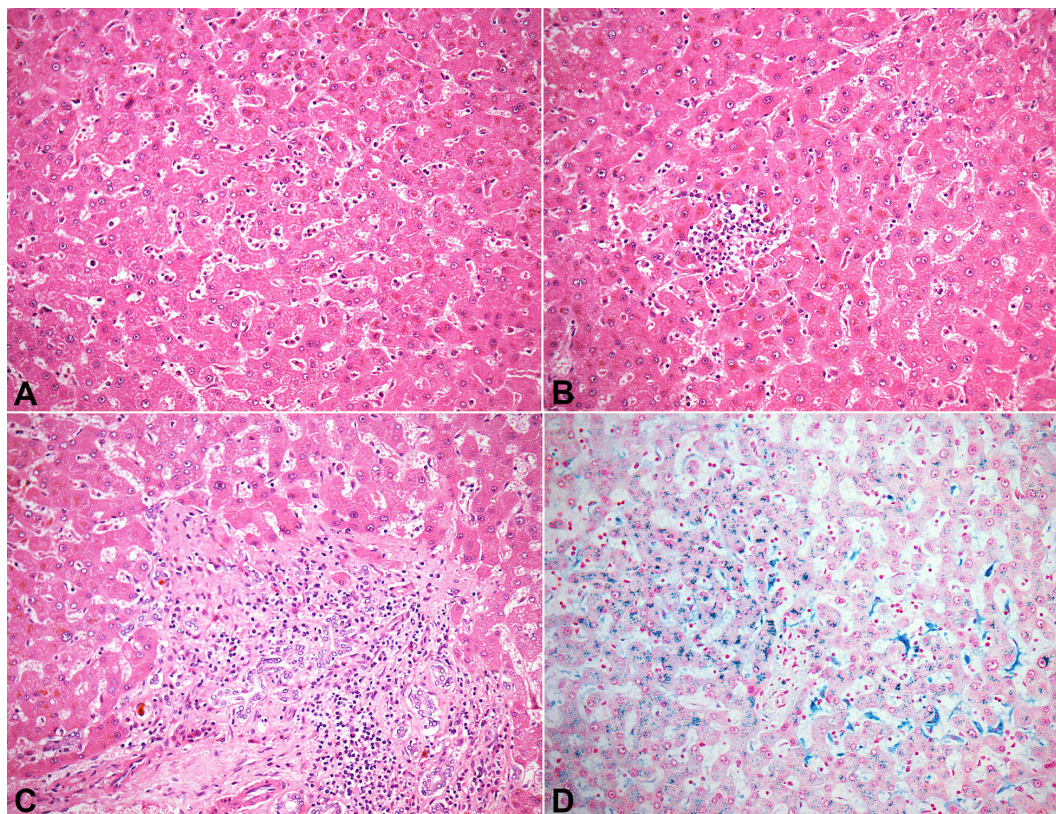
**Figure 5.** **A** – Gross finding of the cross section of the mediastinum showing thrombophlebitis of the left innominate vein (IV) and adjacent abscess; **B** – Panoramic photomicrography of the innominate vein with thrombophlebitis and its rupture in continuity with the mediastinal abscess (HE, 100X); **C** – Discontinuity of the innominate vein elastic layer (Verhoff, 100X); **D** – Gram positive cocci colonies in the mediastinal abscess (Brown-Hopps, 400X). CA = carotid artery; E = esophagus; T = trachea.



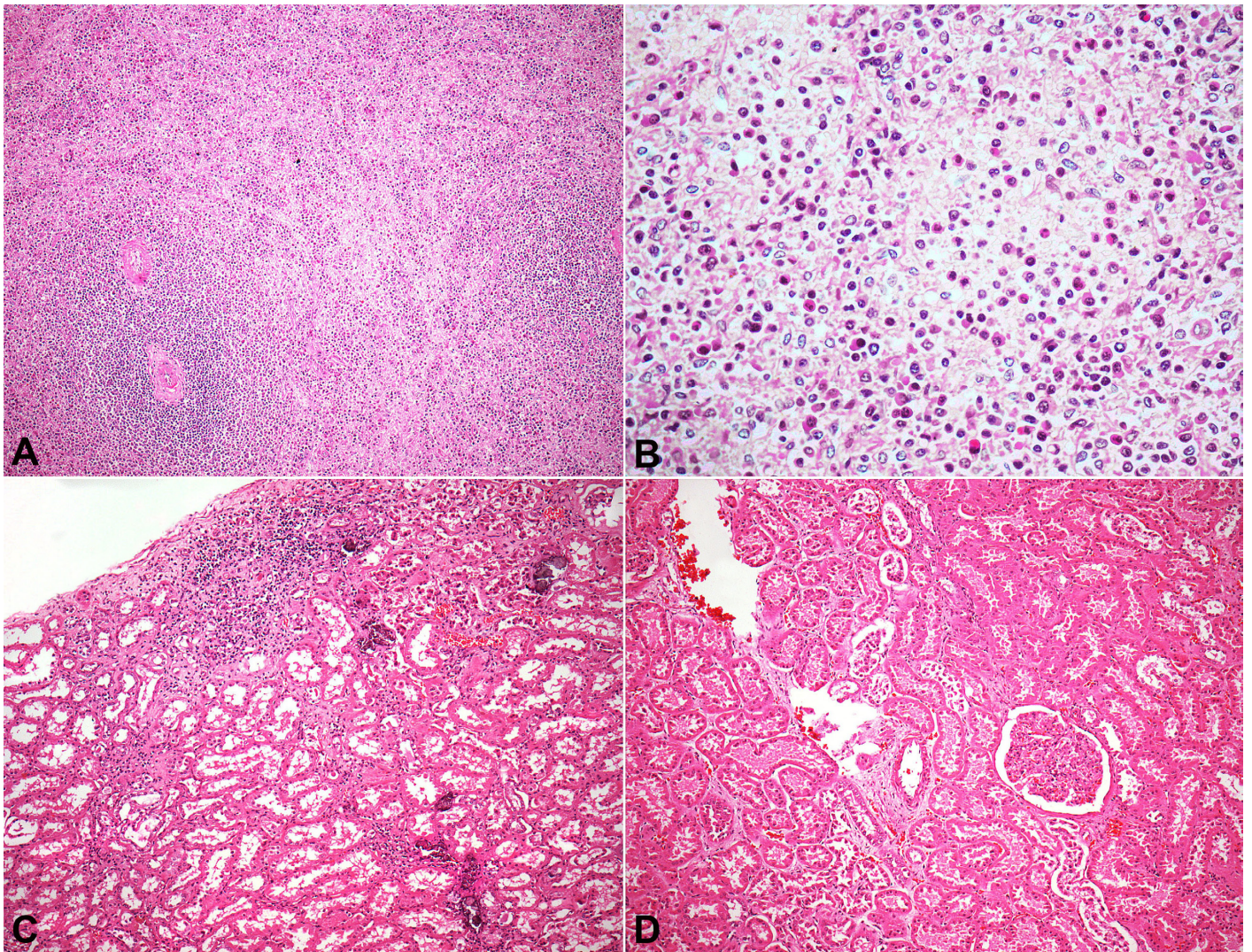
**Figure 6.** **A** – Blood clot within the trachea; **B** – Blood clot within the stomach.



**Figure 7.** **A** – Gross appearance of the pulmonary cut surface showing blood clots within the bronchial tree (arrow). The adjacent alveolar parenchyma presents areas of friable and purplish consolidation; **B** – Photomicrography of the lung showing blood clot within the bronchial lumen, alveolar hemorrhage, and acute inflammatory infiltrate (HE, 25X); **C** – Alveolar hemorrhage (HE, 100X); **D** – Alveolar spaces filled by macrophages and numerous neutrophils consistent with pneumonia (HE, 100X).



**Figure 8.** Photomicrography of the liver. **A** – Mild sinusoidal dilation with intrasinusoidal neutrophils (HE, 100X); **B** – Hepatocyte lobular necrosis with neutrophilic infiltration (HE, 100X); **C** – Portal triad showing mild inflammatory infiltrate with focal cholestasis (HE, 200X); **D** – Hepatocytes and Kupffer cells siderosis (Perls, 100X).



**Figure 9.** Photomicrography of the spleen. **A** – Red pulp congestion (HE, 100X); **B** – Detail of the red pulp with acute splenitis (HE, 400X); **C** – Photomicrography of the kidney showing a scar due to pyelonephritis with basophilic calcification (HE, 100X); **D** – Renal cortical parenchyma with acute tubular necrosis (HE, 100X).

(both weighed 315 g [RV; 313 g]) showed acute tubular necrosis besides focal pyelonephritis scars and a retention cyst (Figure 9).

## DISCUSSION

Oral cavity and pharynx cancer are global public health concerns due to their high frequency, theoretical prevention, and potential for early detection. Up to three-quarters of these neoplasms affect people in developing countries<sup>1</sup> predominating males over the age of 50; although, recently, an increasing incidence among females and the younger population has been observed.<sup>2</sup> Smoking or chewing tobacco, heavy alcohol drinking, and infection by the human papilloma virus (HPV) are well-known increasing risks factors for

oral and pharyngeal cancer. Notwithstanding, more recently, the infection by HPV has been found to be the major cause of pharyngeal cancer, which has been detected in 80% of these tumors.<sup>3,4</sup> Neoplasm of the uvula is very rare with scant case series studies, which is why they are, currently, encompassed among the soft palate tumors. In these cases, the clinical symptoms are varied, but dysphagia and oral bleeding are very probable manifestations.<sup>5</sup> We believe that the patient reported herein, in addition to bad dentition, presented risk factors and epidemiological characteristics consistent with oropharynx malignancy, which added to the intratumoral abscess and the pharyngitis were responsible for the initial complaint (dysphagia) and the severe infections that followed Lemierre's syndrome (LS), mediastinitis, and pneumonia.

Although already reported by Courmont<sup>6</sup> and Cade<sup>7</sup> in 1900, and Frankel<sup>8</sup> in 1919, the French physician and Professor of Bacteriology, Andre Alfred Lemierre,<sup>9</sup> published a paper in 1936 in *The Lancet* on a syndrome characterized by pharyngitis or tonsillitis, fever, and rigors (based on the observation of 20 cases), which usually ensued on the fourth or fifth day after the sore throat. Clinical features usually are accompanied by swelling of the submandibular glands, neck tenderness and edema extending from the angle of the jaw to the clavicle. Although the initial site of infection involved the oropharynx, which was mostly represented by tonsillitis, other primary infection sites such as teeth (which are very probably underreported), ear, sinus, and glandular areas have also been reported.<sup>10-12</sup> Although rare, Lemierre syndrome associated with malignancy has been previously reported,<sup>13,14</sup> however, as far as we know, this is the first report of LS diagnosed at autopsy, where the primary site of infection was an intratumoral abscess of the uvula.

It is likely that *Streptococcus viridans*, which was isolated in our case, had its origin in the periodontal disease and invaded the uvula enabling the infection to reach the pharynx. At the time of Dr. Lemierre's original description, the mortality rate was 90%. However, this rate dropped significantly to 6.4-5% with the advent of antibiotics,<sup>3,15</sup> and the number of cases declined so much that the entity became known as "the forgotten disease."<sup>16,17</sup>

These days, LS frequently affects young patients around the second and third decade of life.<sup>18,19</sup> The oropharynx may be erythematous, with ulcers or pseudomembrane, or may eventually exhibit a normal appearance.<sup>12</sup>

At the autopsy of the cases studied by Dr. Lemierre, the complications were varied and especially represented by pulmonary lesions; virtually all were necrotic infarcts.<sup>9</sup> Similarly, in the series of cases studied by Sinave et al.<sup>12</sup> from 1974 until 1989, pulmonary complications were present in 97%. Apart from pulmonary lesions, metastatic infections may also be seen in the central nervous system, parotid glands, periocular structures, and joints. These septic complications are already present at the time of diagnosis in 90% of cases, demonstrating the rapid progress of the disease.<sup>15</sup> *Fusobacterium necrophorum* (alone or in combination with other agents) is

isolated in up to 90% of cases.<sup>15</sup> The other agents have been identified as *Fusobacterium*, *Eikenella*, *Bacteroides*, *Streptococcus* (viridans streptococci, *Streptococcus bovis*, *Streptococcus milleri*, and group B and C  $\beta$ -hemolytic streptococci), *Peptostreptococcus*, *Staphylococcus*, *Porphyromonas*, *Prevotella*, and *Proteus spp.*<sup>11,12,18,20-25</sup>

Although paucisymptomatic, our patient presented pharyngitis (diagnosed at autopsy), which, reaching the carotid sheath and involving the left internal jugular vein caused pyelphlebitis and thrombosis up to its entrance into the innominate vein.

A peculiarity of our case was the presence of mediastinitis, found at autopsy, which was responsible for the anterior mediastinal enlargement, present at the initial chest radiography. The most likely physiopathological mechanism for the mediastinitis was a descending necrotizing mediastinitis (DNM).<sup>26-28</sup> In this case, the initial site of infection could be a periodontal abscess (not clinically evident) or, more likely, the uvular abscess. Once it reached the carotid sheath, this infection descended to the thoracic cavity, surrounding the innominate vein.

Similarly to LS, DNM is a life-threatening infection, which is frequently associated with poor dental hygiene, diabetes mellitus, intravenous drug or alcoholic abuse, AIDS, and neoplasms.<sup>26,27</sup> The infection usually arises from periodontal or pharyngeal infection and spreads through the deep perivascular sheath of the neck reaching the mediastinum.<sup>27</sup> *S. viridans*, among several other microbiologic agents, is also associated with the etiopathogenesis of the DNM.<sup>27,28</sup>

Both LS and DNM are rare entities and reports of their association are scarce.<sup>29-31</sup>

The immediate cause of death, in this case, was the massive hemoptysis followed by respiratory insufficiency; therefore, it would be reasonable to expect that a vascular rupture into the respiratory tree had occurred. However, a thorough investigation during autopsy failed to find evidence of a venous fistula, an aneurysm, a pseudoaneurysm, or a pulmonary thromboembolism. The only acceptable cause for the hemoptysis was the alveolar hemorrhage due to pneumonia. Although group A streptococci has been described as the etiologic agent of fatal hemorrhagic pneumonia, to our knowledge, this is the first case of



*S. viridans* hemorrhagic pneumonia and hemoptysis as the cause of death.

We believe that our patient was already admitted with the diagnosis of middle lobe pneumonia as a complication of the misdiagnosed LS, which initially responded to the prescribed antibiotic regimen. During the following days, new episodes of septic embolism may have occurred extending the pulmonary involvement and being responsible for the massive hemoptysis.

Unfortunately, neither LS nor the mediastinitis were diagnosed during the patient's life, and he sought medical attention late when the extent of the infection was significant, which prevented a satisfactory outcome with the clinical treatment.

Thus, we highlight the uvula as a primary site of infection that can cause LS and DNM. We also alert clinicians to be aware of these symptoms for this diagnosis.

## REFERENCES

- Lambert R, Sauvaget C, de Camargo Cancela M, Sankaranarayanan R. Epidemiology of cancer from the oral cavity and oropharynx. *Eur J Gastroenterol Hepatol.* 2011;23(8):633-41. <http://dx.doi.org/10.1097/MEG.0b013e3283484795>. PMID:21654320.
- Scully C, Kirby J. Statement on mouth cancer diagnosis and prevention. *Br Dent J.* 2014;216(1):37-8. <http://dx.doi.org/10.1038/sj.bdj.2013.1235>. PMID:24413123.
- Weatherspoon DJ, Chattopadhyay A, Boroumand S, Garcia I. Oral cavity and oropharyngeal cancer incidence trends and disparities in the United States: 2000-2010. *Cancer Epidemiol.* 2015;39(4):497-504. <http://dx.doi.org/10.1016/j.canep.2015.04.007>. PMID:25976107.
- Kreimer AR, Clifford GM, Boyle P, Franceschi S. Human papillomavirus types in head and neck squamous cell carcinomas worldwide: a systematic review. *Cancer Epidemiol Biomarkers Prev.* 2005;14(2):467-75. <http://dx.doi.org/10.1158/1055-9965.EPI-04-0551>. PMID:15734974.
- Overton LJ, Fritsch VA, Lentsch EJ. Squamous cell carcinoma of the uvula: an analysis of factors affecting survival. *Laryngoscope.* 2013;123(4):898-903. <http://dx.doi.org/10.1002/lary.23648>. PMID:23529880.
- Courmont PCA. Sur une septic-pyohemie de l'homme stimulant la peste et cause par un streptobacille anaerobie. *Archives de med exp et d'anat path.* 1900;4. [in French].
- Vohra A, Saiz E, Ratzan KR. A young woman with a sore throat, septicaemia, and respiratory failure. *Lancet.* 1997;350(9082):928. [http://dx.doi.org/10.1016/S0140-6736\(97\)05261-6](http://dx.doi.org/10.1016/S0140-6736(97)05261-6). PMID:9314872.
- Fränkel E. Über postanginöse Pyämie. *Virchow Arch.* 1925;254(3):639-55.
- Lemierre A. On Certain Septicæmias due to anaerobic organisms. *Lancet.* 1936;227(5874):701-3. [http://dx.doi.org/10.1016/S0140-6736\(00\)57035-4](http://dx.doi.org/10.1016/S0140-6736(00)57035-4).
- Kuppalli K, Livorsi D, Talati NJ, Osborn M. Lemierre's syndrome due to *Fusobacterium necrophorum*. *Lancet Infect Dis.* 2012;12(10):808-15. [http://dx.doi.org/10.1016/S1473-3099\(12\)70089-0](http://dx.doi.org/10.1016/S1473-3099(12)70089-0). PMID:22633566.
- Wilson P, Tierney L. Lemierre syndrome caused by *Streptococcus pyogenes*. *Clin Infect Dis.* 2005;41(8):1208-9. <http://dx.doi.org/10.1086/444565>. PMID:16163643.
- Sinave CP, Hardy GJ, Fardy PW. The Lemierre syndrome: suppurative thrombophlebitis of the internal jugular vein secondary to oropharyngeal infection. *Medicine.* 1989;68(2):85-94. <http://dx.doi.org/10.1097/00005792-198903000-00002>. PMID:2646510.
- Winters R, Amedee R. Squamous cell carcinoma of the palate presenting as Lemierre syndrome. *J La State Med Soc.* 2010;162(6):343-4. PMID:21294491.
- Rey P, Sauvet P, Bernard P, Kull E, Talarmin F. Syndrome de Lemierre secondaire à une adénopathie cervicale maligne. *Presse Med.* 2000;29(16):1460. PMID:11039089.
- Chirinos JA, Lichtstein DM, Garcia J, Tamariz LJ. The evolution of Lemierre syndrome: report of 2 cases and review of the literature. *Medicine.* 2002;81(6):458-65. <http://dx.doi.org/10.1097/00005792-200211000-00006>. PMID:12441902.
- Marcello CE, Kim EIM, Smeili LAA, Bianqui L, Bazzi M. Síndrome de Lemierre: a doença esquecida. *Autops Case Rep.* 2011;1(3):53-8. <http://dx.doi.org/10.4322/acr.2011.009>.
- Bliss SJ, Flanders SA, Saint S. Clinical problem-solving: a pain in the neck. *N Engl J Med.* 2004;350(10):1037-42. <http://dx.doi.org/10.1056/NEJMcps032253>. PMID:14999116.
- Wong AP, Duggins ML, Neil T. Internal jugular vein septic thrombophlebitis (Lemierre syndrome) as a complication of pharyngitis. *J Am Board Fam Med.* 2015;28(3):425-30. <http://dx.doi.org/10.3122/jabfm.2015.03.140131>. PMID:25957375.
- Armstrong AW, Spooner K, Sanders JW. Lemierre's syndrome. *Curr Infect Dis Rep.* 2000;2(2):168-73. <http://dx.doi.org/10.1007/s11908-000-0030-z>. PMID:11095853.
- Tsai MS, Huang TC, Liu JW. Lemierre's syndrome caused by viridans streptococci: a case report. *J Microbiol Immunol Infect.* 1999;32(2):126-8. PMID:11561577.

21. Ricondo LR, Gómez MJR, Cantador JA, Bravo-Rodríguez FA. Síndrome de Lemierre: trombosis de seno cavernoso y oclusión de arteria carótida interna secundarios a sinusitis esfenoidal aguda. *Acta Otorrinolaringol Esp.* 2013;64(1):75-7. <http://dx.doi.org/10.1016/j.otorri.2011.08.005>. PMID:22424548.
22. Jankowich M, El-Sameed YA, Abu-Hijleh M. A 21-year-old man with fever and sore throat rapidly progressive to hemoptysis and respiratory failure. Diagnosis: Lemierre syndrome with *Fusobacterium necrophorum* sepsis. *Chest.* 2007;132(5):1706-9. <http://dx.doi.org/10.1378/chest.07-0631>. PMID:17998376.
23. Gargallo E, Nuevo JA, Cano JC, Castuera AI, Andueza JA, Fernández M. Lemierre syndrome: several clinical features of "a forgotten disease". *Enferm Infecc Microbiol Clin.* 2010;28(10):701-5. <http://dx.doi.org/10.1016/j.eimc.2010.02.012>. PMID:20570017.
24. Olson KR, Freitag SK, Johnson JM, Branda JA. Case 36-2014: an 18-year-old woman with fever, pharyngitis, and double vision. *N Engl J Med.* 2014;371(21):2018-27. <http://dx.doi.org/10.1056/NEJMcpc1310001>. PMID:25409375.
25. Agrafiotis M, Moulara E, Chloros D, Tsara V. Lemierre syndrome and the role of modern antibiotics and therapeutic anticoagulation in its treatment. *Am J Emerg Med.* 2015;33(5):733.e3-4. <http://dx.doi.org/10.1016/j.ajem.2014.10.029>. PMID:25455045.
26. Weaver E, Nguyen X, Brooks MA. Descending necrotising mediastinitis: two case reports and review of the literature. *Eur Respir Rev.* 2010;19(116):141-9. <http://dx.doi.org/10.1183/09059180.00001110>. PMID:20956183.
27. Cirino LMI, Elias FM, Almeida JLJ. Descending mediastinitis: a review. *Sao Paulo Med J.* 2006;124(5):285-90. <http://dx.doi.org/10.1590/S1516-31802006000500011>. PMID:17262162.
28. Cai XY, Zhang WJ, Zhang ZY, Yang C, Zhou LN, Chen ZM. Cervical infection with descending mediastinitis: a review of six cases. *Int J Oral Maxillofac Surg.* 2006;35(11):1021-5. <http://dx.doi.org/10.1016/j.ijom.2006.06.021>. PMID:17023143.
29. Uduma FU, Yarouda M, Wali M. An unusual presentation of bilateral internal jugular venous thrombosis: a case report. *Glob J Health Sci.* 2011;3(1):237-41. <http://dx.doi.org/10.5539/gjhs.v3n1p237>.
30. Malis DD, Busaidy KF, Marchena JM. Lemierre syndrome and descending necrotizing mediastinitis following dental extraction. *J Oral Maxillofac Surg.* 2008;66(8):1720-5. <http://dx.doi.org/10.1016/j.joms.2007.12.002>. PMID:18634963.
31. Riordan T. Human infection with *Fusobacterium necrophorum* (Necrobacillosis), with a focus on Lemierre's syndrome. *Clin Microbiol Rev.* 2007;20(4):622-59. <http://dx.doi.org/10.1128/CMR.00011-07>. PMID:17934077.

**Conflict of interest:** None

**Submitted on:** July 31, 2015

**Accepted on:** August 20, 2015

### Correspondence

Hassan Rahhal

Internal Medicine Department

Hospital das Clínicas - Faculty of Medicine - University of São Paulo

Av. Dr. Enéas Carvalho de Aguiar, 155 8th floor - São Paulo/SP - Brazil

CEP: 05403-000

Phone: +55 11 26616300

**E-mail:** hassan.r@hc.fm.usp.br