

Infertility diagnosis in jaguar (*Panthera onca*): case report

Diagnóstico de infertilidade em onça pintada (*Panthera onca*): relato de caso

Caroline Vieira de BARROS¹; Natália Martins GALVÃO¹; Silvia Laís CROCE¹; Talyta Finoti Ferreira TELES¹; Thalita Amorim de SOUZA¹; Valéria Dias de ARAÚJO¹; Vitor Hugo MORENO¹; Victor Luiz ROCHA¹; Guilherme Sellera GODOY¹; Sandra Peres FERREIRA¹; Tatiana Paula Alvarenga CARVALHO¹; Daniel de Souza Ramos ANGRIMANI²

¹ Centro Universitário Monte Serrat, Curso de Medicina Veterinária, Santos – SP, Brazil

² Universidade de São Paulo, Faculdade de Medicina Veterinária e Zootecnia, São Paulo – SP, Brazil

Abstract

This work reports one case of infertility in a male jaguar (*Panthera onca*) aged 21 years and weighing 125 kg. Changes in sperm due to chronic stress, inadequate food handling and reproductive senescence are emphasized.

Keywords: *Panthera onca*. Infertility. Reproductive senescence. Wild animals reproduction.

Resumo

O presente trabalho relata um caso de infertilidade em uma onça-pintada (*Panthera onca*), macho, de 21 anos e 125 kg. São ressaltadas as alterações ocorridas nos espermatozoides, devido a estresse crônico, manejo alimentar inadequado e senescência reprodutiva.

Palavras-chave: *Panthera onca*. Infertilidade. Senescência reprodutiva. Reprodução animais silvestres.

Correspondence to:

Daniel de Souza Ramos Angrimani
Universidade de São Paulo, Faculdade de Medicina
Veterinária e Zootecnia
Av. Prof. Dr. Orlando Marques de Paiva, n. 87
CEP 05508-270, São Paulo, SP, Brazil
e-mail: angrimani@gmail.com

Received: 29/02/2016

Approved: 15/08/2016

Jaguar (*Panthera onca*) is considered an endangered species in Brazil (MORATO et al., 2004). Among the factors that have threatened this population, loss of habitat mainly associated with agricultural expansion stands out (MORATO et al., 1999). Therefore, to reduce the loss of genetic diversity, targeted efforts to breeding animals in captivity should be applied (MICHELETTI et al., 2012). But the major problem is the chronic stress condition that animals develop in captivity due to

limited space, management deficiencies, enclosure conditions (structure, hygiene and adaptations for the species), nutrition and clinical monitoring (MICHELETTI et al., 2012). Moreover, captive jaguars live an average of 20 years, in some cases, 27 years; conversely, in the natural environment, their lifetime is estimated at between 12 and 16 years (MIRANDA; JOHN, 2010). As a consequence of this senescence and captivity conditions, effects on spermatogenesis and ovulation can also occur, which may promote perinatal morbidity, mortality and even infertility (MORATO et al., 2004). Therefore, it is necessary to discuss and understand the reasons that trigger infertility in captive animals.

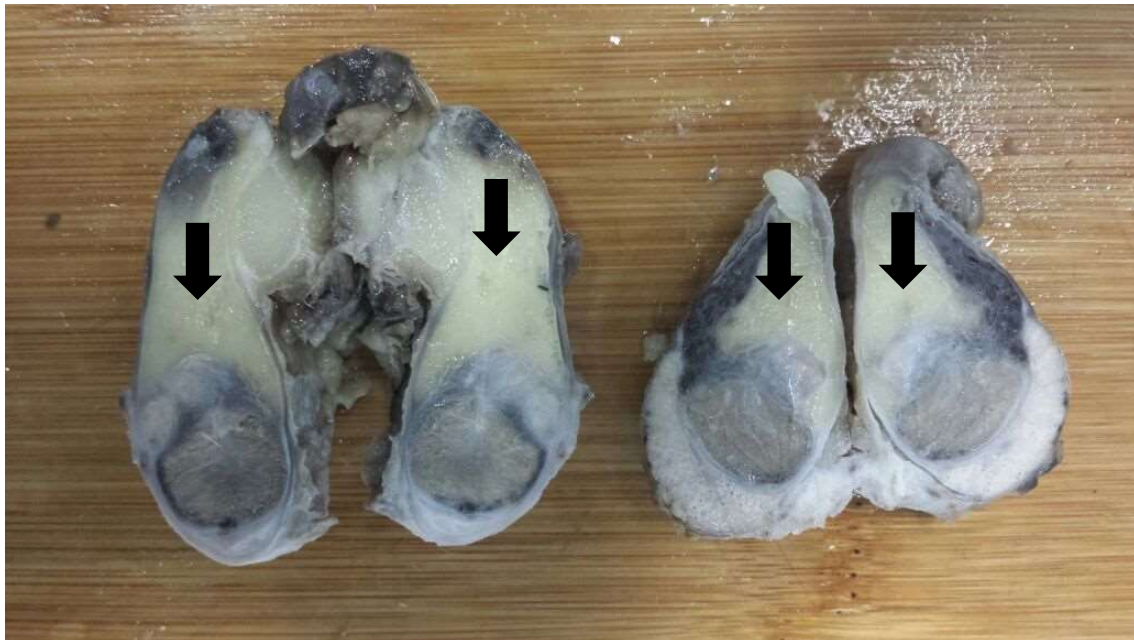
This study was carried out at the Ecological Park facilities of Voturuá, São Vicente (SP). A 21-year-old male *Panthera onca* weighing 125 kg was used. The animal was born in captivity and has no reproductive history. The enclosure was barred in a room with public view, with access to bath tank and night shelter.

The animal showed injuries in the forelimb, anorexia and prostration. Chemical restraint was performed for curative purposes using ketamine (10 mg/kg) and xylazine (1 mg/kg), intramuscularly administered. Sedation was maintained with diazepam (10 mg/kg) during the procedure.

After chemical restraint, breeding soundness examination of the animal was carried out. Few spines were found on the penis. The right testicle had of 2 cm in width and 4 cm in height and the left testicle 2.54 cm and 3 cm, respectively, values lower than previously described for jaguars (MORATO et al., 1999). Both had flaccid consistency. Blood was collected for the dosage of testosterone conducted with commercial kit (Testosterone Coat-ACount; Diagnostic Products Corporation, Los Angeles, CA, USA), where the value of 0.32ng/ml was found, while the reference value was 1.0 to 6.0ng/mL (MORATO et al., 2004). The seminal collection was carried out following the pattern of electrical stimulation

procedure (PLATZ; SEAGER, 1978). The Torjet 65C[®] device (Eletrovet, São Paulo, SP, Brazil) was used. The collected semen was analyzed in conventional microscope in which azoospermia was found. Due to the advanced age of the animal, his critical health condition (anorexia and prostration) and anesthetic complications during the curative procedure, the jaguar experienced cardiac arrest and death. The necropsy after the macroscopic examination revealed cardiac arrest as the cause of death. Moreover, scrotum, testes and epididymis were macroscopically evaluated. During examination, excess adipose tissue adjacent to the gonads was observed (Figure 1). Histopathological examination was performed with testis and epididymis after fixation in 10% formalin, where diffuse and severe interstitial fibrosis associated with atrophy of the seminiferous tubules was detected. In the rare seminiferous tubules found, no sperm was observed.

Figure 1 – Macroscopic exam of the testis. Excess of adipose tissue adjacent to the gonads (arrows) – Santos – 2016



According to Hafez and Hafez (2004) and Morato et al. (1999), sperm changes may be due to congenital, nutritional, metabolic causes, chronic stress and by the aging process. In fact, aged animals have a decrease in

testosterone production by the Leydig cells (CUNNINGHAM, 2008). In humans, for example, testosterone decreases gradually after 40 years (MORLEY, 2000). To our knowledge, these data have

not been studied in jaguars; however, in this study, the animal had a lower testosterone rate and was 21 years old, whereas the lifetime of a wild jaguar is estimated at 12 to 16 years (MIRANDA; JOHN, 2010). Therefore, we presume that this age for *Panthera onca* may indicate the reproductive senescence, which can cause a lower testosterone production and poor sperm quality.

Moreover, Miranda and John (2010) estimate that the average weight of an adult *Panthera onca* is between 56 to 96 kg, and in the Brazilian Pantanal, there is the presence of larger animals, reaching up to 100 kg. The animal of this study was overweight (125

kg), contributing to the accumulation of adipose tissue adjacent to the testicle, leading to fibrosis and atrophy, thus hampering testosterone production by the Leydig cells (CUNNINGHAM, 2008). Thus, preventive examinations in order to detect pathological changes are required. Furthermore, it is possible to maximize the reproductive potential of captive animals using seminal biotechnologies (i.e. cryopreservation) during the reproductive age. In addition, measures such as environmental enrichment in the enclosure, mixed with a physical activity routine and proper nutrition are necessary to good quality of life of captive animals.

References

CUNNINGHAM, J. G. **Tratado de fisiologia veterinária**. Rio de Janeiro: Elsevier, 2008. 710 p.

HAFEZ, E. S. E.; HAFEZ, B. **Reprodução animal**. Barueri: Manole, 2004. 513 p.

MICHELETTI, T.; CUBAS, Z. S.; MORAES, W.; OLIVEIRA, M. J.; MOREIRA, N. Reprodução natural de felídeos selvagens em cativeiro: dificuldades e orientações. **Revista Brasileira de Reprodução Animal**, v. 36, n. 1, p. 39-43, 2012. Available from: <<https://goo.gl/HTxTJ1>>. Viewed: 15 Feb. 2016.

MIRANDA, E. E; JOHN, L. **Jaguar: o rei das Américas**. São Paulo: Metalivros, 2010. 299 p.

MORATO, R. G.; GUIMARÃES, M. A. B. V.; FERREIRA, F.; VERRESCHI, I. T. N.; BARNABE, R. C. Reproductive characteristics of captive male jaguars (*Panthera onca*). **Brazilian Journal of Veterinary Research and Animal**

Science, v. 36, n. 5, p. 262-266, 1999. doi: 10.1590/S1413-95961999000500008.

MORATO, R. G.; BUENO, M. G.; MALMHEISTER, P.; VERRESCHI, I. T. N.; BARNABE, R. C. Changes in the fecal concentrations of cortisol and androgen metabolites in captive male jaguars (*Panthera onca*) in response to stress. **Brazilian Journal of Medical and Biological Research**, v. 37, n. 12, p. 1903-1907, 2004. doi: 10.1590/S0100-879X2004001200017.

MORLEY, J. E. Testosterone treatment in older men: effects on the prostate. **Endocrine Practice**, v. 6, n. 2, p. 218-221, 2000. doi: 10.4158/EP.6.2.218.

PLATZ, C. C.; SEAGER, W. J. Semen collection by electroejaculation in the domestic cat. **Journal of the American Veterinary Medical Association**, v. 173 n. 10, p. 1353-1355, 1978.