

Hemangiosarcoma at the base of the left atrium of a dog with mitral and tricuspid valve degeneration – case report

Hemangiossarcoma na base do átrio esquerdo de um cão com degeneração da válvula mitral e tricúspide – relato de caso

Emiliana Andrades FIORINI¹; Tatiane Cristina Batista SANTOS¹; Luana Canassa ALVES¹; Rogério MORETTI²; Alexandre HATAKA¹; Camila Dias PORTO¹; Rodrigo Prevedello FRANCO¹

¹ Universidade de Marília, Faculdade de Ciências Agrárias, Curso de Medicina Veterinária, Marília – SP, Brazil

² Médico veterinário autônomo, Marília – SP, Brazil

Abstract

Hemangiosarcoma (HSA) is a malignant neoplasm originating from the vascular endothelium, with high metastatic power and commonly described in the spleen, liver, and right atrium. Thus, the objective of the present study is to report the occurrence of HSA at the base of the left atrium of a male, elderly, Lhasa Apso dog, treated with cyanosis, orthopedic position, cough. In the physical examination, the presence of crackling was observed in pulmonary lobes, murmur in focus of mitral and tricuspid grade IV\VI. The recommended emergency therapy was performed until the clinical improvement of the animal. After echocardiography, mitral and tricuspid valvular degeneration was confirmed, as well as the presence of an irregular, mixed echocardiogram, extra-cardiac, immobile at the base of the left atrium, measuring 2.9 x 1.44 cm in diameter. The clinical therapy established stabilized the clinical picture for 128 days, with recurrence of pulmonary edema and severe hemorrhagic pleural effusion, with the owners opting for euthanasia of the animal and necropsy confirming the definitive diagnosis of extrahepatic SAH at the base of the left atrium.

Keywords: Neoplasia. Hemangiosarcoma. Left atrium. Dog.

Resumo

O hemangiossarcoma (HSA) é uma neoplasia maligna originada no endotélio vascular, com alto poder metastático e comumente descrito no baço, fígado e átrio direito. Assim, o objetivo deste trabalho é relatar a ocorrência do HSA na base do átrio esquerdo de um cão, macho, idoso, da raça Lhasa Apso, atendido apresentando cianose, posição ortopneica e tosse. No exame físico foi observado presença de crepitação em lobos pulmonares e sopro em foco de mitral e tricúspide grau IV\VI. Foi realizada terapia emergencial preconizada até a melhora clínica do animal, e após a ecocardiografia confirmou-se a degeneração valvular mitral e tricúspide, bem como a presença de uma imagem irregular, de ecogenicidade mista, extracardiaca e imóvel na base do átrio esquerdo, medindo 2,9 x 1,44 cm de diâmetro. A terapia clínica instituída estabilizou o quadro clínico por 128 dias, havendo recidiva do edema pulmonar e efusão pleural hemorrágica grave, com os proprietários optando pela eutanásia do animal e a necropsia, confirmando o diagnóstico definitivo do HSA extracardiaco na base do átrio esquerdo.

Palavras-chave: Neoplasia. Hemangiossarcoma. Átrio esquerdo. Cão.

Correspondence to:

Rodrigo Prevedello Franco
Universidade de Marília, Faculdade de Ciências Agrárias,
Curso de Medicina Veterinária
Av. Hygino Muzzy Filho, 1001
CEP 17525-902, Marília, SP, Brazil
e-mail: vetrpf@yahoo.com.br

Received: 15/05/2017

Approved: 10/10/2017

Hemangiosarcoma (HSA) is a malignant neoplasm of endothelial cells of aggressive behavior, with great

capacity of infiltration and metastases in the liver, spleen, heart, lung, mesentery, skin, and subcutaneous tissue (VERBEKE et al., 2012). In addition, atrioventricular junction and left ventricle (PALACIO et al., 2006) have been reported in the literature. The intensity of the cardiovascular changes determined by this neoplasm may vary according to its location, size, presence of pericardial effusion, and cardiac tamponade (FERREIRA et al., 2011). Clinical findings are generally congestive heart failure (CHF), hypovolemic shock caused by

neoplastic mass rupture and arrhythmias (WARMAN et al., 2006). The definitive diagnosis is made through clinical history, radiographic and echocardiographic findings, and samples of paracentesis or thoracentesis sent for cytological and histopathological examination (BROWN et al., 1985). The surgical treatment is based on pericardiectomy and tumor resection, providing a palliative reduction of the signs, followed or not by a coadjuvant chemotherapy (WEISSE et al., 2005). The clinical treatment consists of the chemotherapy protocol to be performed as adjuvant to the surgical one, with good results in the control of metastases and increase

of the patient's life expectancy (WEISSE et al., 2005). The indicated chemotherapy protocols are VAC I and VAC II, which consist of administration of the combination of Doxorubicin, Cyclophosphamide, and Vincristine (FREIRE, 2009). Since the clinical signs observed in dogs with thoracic HSA are similar to those described in patients with CHF with mitral and tricuspid valve degeneration (DVT), differential diagnosis is recommended as a function of respiratory compromise and hemodynamic changes (NELSON; COUTO, 2010). Therefore, the aim of the present study is to report the occurrence of left atrial HSA in a dog with DVT.

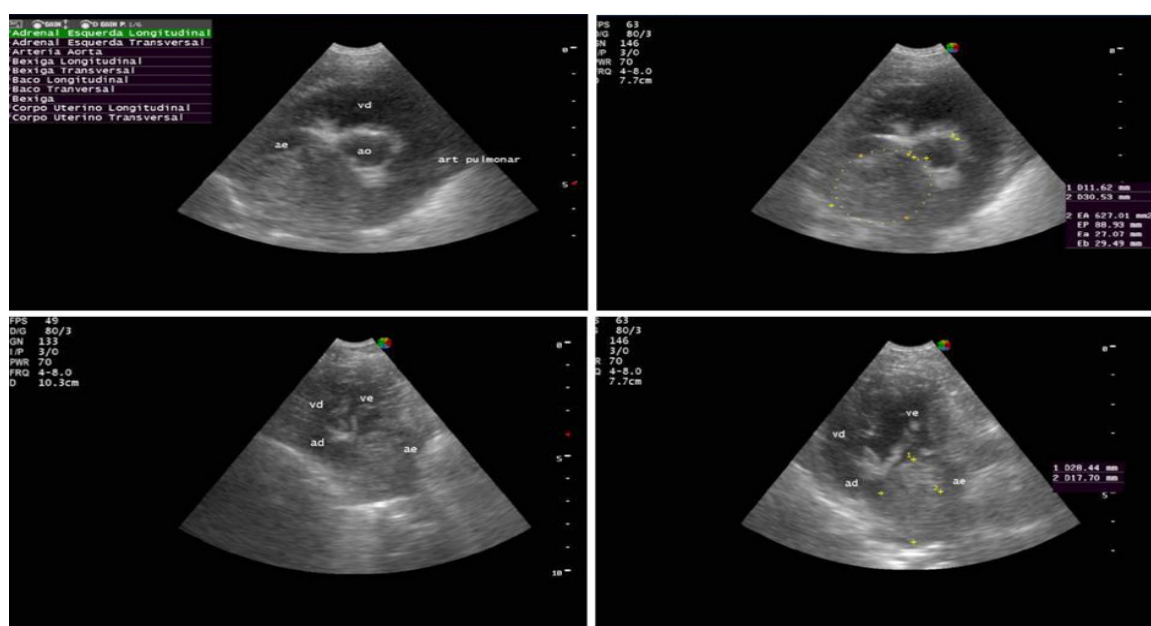


Figure 1 – Echocardiographic images of a male dog with HSA, obtained through the right and left parasternal window, showing circular, extracardiac images, overlapping the left atrium

A 13-year-old Lhasa Apso male dog arrived for clinical care with cyanosis, orthopedic position, cough, and progressive weight loss five days earlier. Physical examination revealed crackling in pulmonary lobes, cyanotic mucosa, murmur in focus of mitral and tricuspid grade IV\VI (holosystolic), body score three, and hepatomegaly. Outpatient treatment based on oxygen therapy and furosemide (4 mg/kg) was administered through two intravenous boluses every two hours, followed by continuous infusion (0.1 mg/kg/h) for two hours, until the clinical improvement of the animal was obtained. Laboratory tests showed normocytic normochromic anemia, renal azotemia, hyperphosphataemia, and increased liver enzymes. The chest X-ray revealed pulmonary edema

and cardiomegaly. The electrocardiogram showed fifteen premature ventricular complexes (CVP) in three minutes and echocardiography confirmed the presence of DVTM with mild pulmonary hypertension and an irregular, mixed echogenicity image Cardiac, immobile at the base of the left atrium, measuring 2.9 x 1.44 cm in diameter. Thus, the presence of an extra-cardiac neoplasia and functional class D-DVMT was confirmed. With clinical improvement of the animal, benazepril hydrochloride, spironolactone, furosemide, and sildenafil of continuous use were prescribed together with ranitidine and prednisolone for 5 days, both orally (VO). In the clinical reassessment in 7 days, the clinical improvement of the animal was observed, with the progressive withdrawal in 10 days of prednisolone

and the inclusion of aluminum hydroxide by VO, and the remaining medications were maintained. A new clinical, radiographic, electrocardiographic, and echocardiographic evaluation was performed 30 days after the start of therapy, confirming the absence of pulmonary edema and ventricular arrhythmias, but maintenance of the extracardiac image at the base of the left atrium (Figure 1). However, the animal still had episodes of sporadic dry cough, and an antitussive based on clobutinol hydrochloride and doxylamine succinate was then prescribed every 12 hours for 15

days. Animal was clinically stable for 128 days, but with recurrence of pulmonary edema and the presence of acute hemorrhagic pleural effusion, the tutors ended up opting for euthanasia due to the seriousness of the clinical picture and financial unavailability. The definitive diagnosis was made through necropsy findings and histopathological examination of the tumor mass (Figures 2 and 3), confirming extracardiac HSA in the base of the left atrium with extension and involvement of the aorta and pulmonary arteries, severe hemorrhagic pleural effusion and DVTM (Figure 1).

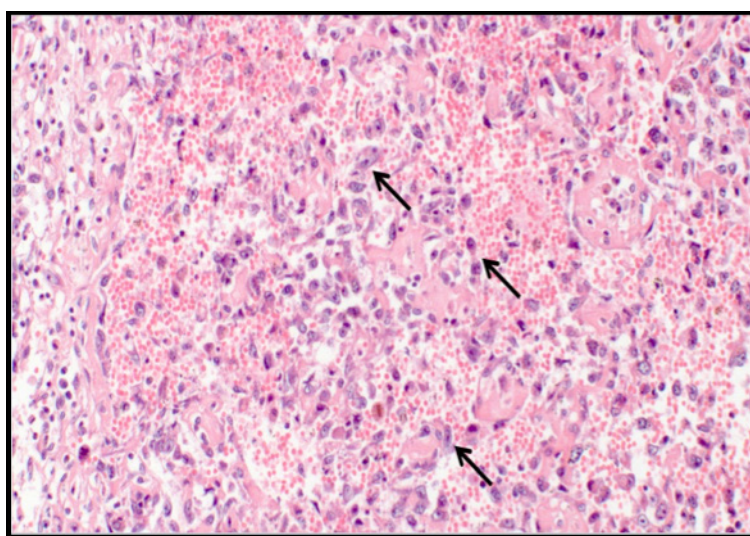


Figure 2 – Photomicrograph of left atrial hemangiosarcoma. Note the atypical endothelial cells (arrows). HE, 20x objective

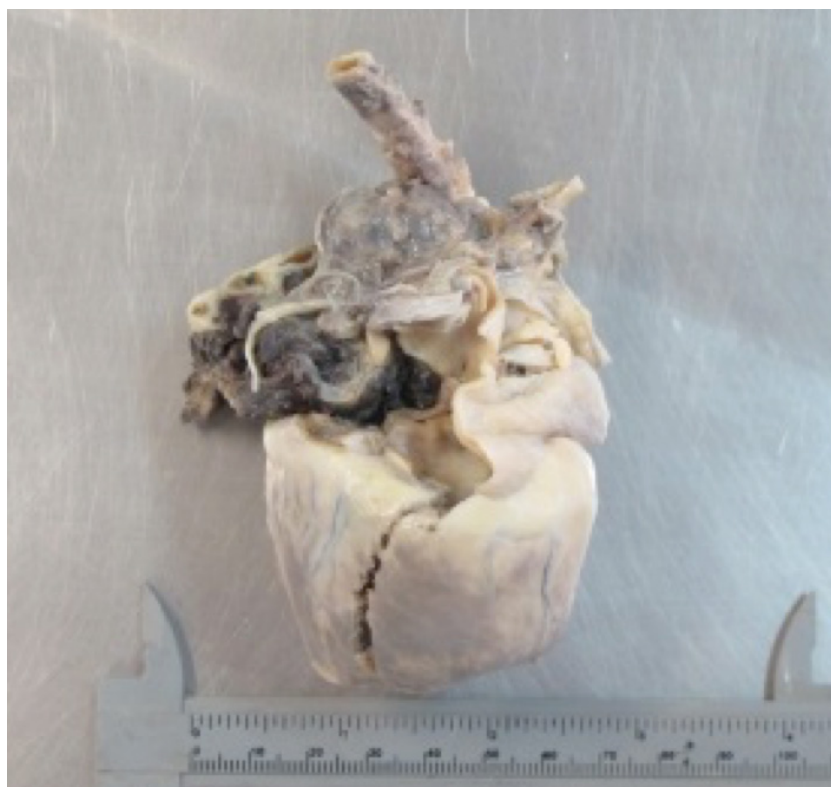

Figure 3 – Neoplastic mass in left atrium base, involving aorta and pulmonary arteries

HSA has become the neoplasia commonly found in dogs, appearing mainly in the atria, accompanied by metastasis in other organs such as spleen, liver, and lung (GIRARD et al., 1999). In the described patient no metastases were found in other organs at the necropsy examination, but the presence of neoplasia, extraphysical mass, was confirmed in the left atrium base by histopathology, identifying as HSA.

Clinical signs observed during clinical care, complementary examinations and established therapeutics are compatible and recommended for the diagnosis and treatment of dogs with functional class D DVMT (ATKINS et al., 2009; FRANCO et al., 2011) cardiogenic pulmonary edema. The clinical and echocardiographic findings described with regard to the left atrial base neoplasia corroborating with the findings reported by Brown et al. (1985) and Ferreira et al. (2011). The ventricular arrhythmia observed during electrocardiography performed at the time of clinical care was described by Warman et al. (2006) as one of the findings in patients with SAH. However, myocardial hypoxia and cardiac output reduction are observed in patients with class D MVDM, in which they justify the occurrence of premature ventricular complexes. With clinical stabilization, the absence of arrhythmias was noted, as in the present case report (GOMES, 2016).

The hematological findings of dogs with SAH are non-specific, but normochromic normocytic anemia, renal azotemia, hyperphosphatemia, and increased liver enzymes are described in dogs with SAH and DVMT (WEISSE et al., 2005). Anemia is caused by a shift of blood from the circulation to the major neoplastic nodules (FERREIRA et al., 2011). Renal azotemia and hyperphosphataemia are commonly described in dogs with DVTD due to impairment of renal perfusion (MARTINELLI et al., 2016). However, the increase in liver enzymes is usually due to the presence of metastasis (FREIRE, 2009).

References

ATKINS, C.; BONAGURA, J.; ETTINGER, S.; FOX, P.; GORDON, S.; HAGGSTROM, J.; HAMLIN, R.; KEENE, B.; LUIS-FUENTES, V.; STEPIEN, R. Guidelines for the diagnosis and treatment of canine chronic valvular heart disease. **Journal of Veterinary Internal Medicine**, v. 23, n. 6, p. 1142-1150, 2009. doi: 10.1111/j.1939-1676.2009.0392.x.

Clinical therapy instituted in the maintenance of the CHF (REYNOLDS et al., 2012), together with the combination of prednisolone aimed at the reduction of the neoplastic inflammatory process and cough suppression (RUTHERFORD et al., 2016). Ranitidine hydrochloride is a histamine H2 receptor antagonist and aluminum hydroxide has a phosphorus chelating action in an attempt to reduce serum phosphorus levels (BECKER, 2011). After 128 days, remission of pulmonary edema and hemorrhagic pleural effusion occurred. Due to the severity of the clinical situation and the financial unavailability of the tutors, they chose to perform euthanasia (CFMV, 2012). The justification for the worsening of the clinical picture was confirmed in the necropsy examination, confirming the extracardiac HSA on the basis of the left atrium and base of the aortic and pulmonary arteries, suggesting the occurrence of compression of the atrium and the great arteries, leading to worsening of the CHF. In addition to the rupture of tumor vesicles causing acute pleural hemorrhagic effusion, facts described by Ferreira et al. (2011) attested that patients with HSA due to hypovolemic shock due to acute hemorrhage due to rupture of tumor vesicles located in peritoneal and/or pericardial cavities.

According to Brown et al. (1985), the definitive diagnosis of SAH is given by means of histopathological examination, as performed in the present report, with its predisposition to occur at the base of the right atrium (PALACIO et al., 2006). However, the present study describes its presentation at the base of the left atrium with involvement of the aorta and pulmonary arteries, according to the findings of the necropsy performed.

The description and interpretation of the clinical findings and the complementary tests performed confirmed the occurrence of left atrial hemangiosarcoma in a dog with DVT.

BROWN, N. O.; PATNAIK, A. K.; MACEWEN, E. G. Canine hemangiosarcoma: retrospective analysis of 104 cases. **Journal of the American Veterinary Medical Association**, v. 186, n. 1, p. 56-58, 1985.

BECKER, T. M. **Abordagem terapêutica no paciente geriátrico**. 2011. 97 f. Monografia (Graduação) –

Universidade Federal do Rio Grande do Sul, Porto Alegre, 2011.

CONSELHO FEDERAL DE MEDICINA VETERINÁRIA (CFMV). **Guia brasileiro de boas práticas em eutanásia em animais: conceitos e procedimentos recomendados.** Brasília, DF: CFMV, 2012.

FREIRE, G. P. Z. **Hemangiossarcoma canino: revisão de literatura.** 2009. 33 f. Monografia (Especialização) – Universidade Federal Rural do Semi-Árido, Curitiba, 2009.

FERREIRA, A. R. A.; ORIÁ, A. P.; MOREIRA, E. L. T.; SILVEIRA, C. P. B.; MARINHO, T. C. M. S.; VIEIRA FILHO, C. H. C.; BURGUER, C. P.; COSTA NETO, J. M. Hemangiossarcoma cardíaco em cão: relato de caso. **Medicina Veterinária**, v. 5, n. 4, p. 17-25, 2011.

FRANCO, R. P.; CHAMPION, T.; PASCON, J. P. E.; NETO, G. B. P.; JUNIOR, D. P.; CAMACHO, A. A. Utilização do maleato de enalapril, furosemida, espirolactona e suas associações em cães com doença degenerativa mixomatosa da válvula mitral. **Ars Veterinária**, v. 27, n. 2, p. 85-93, 2011.

GOMES, M. C. P. **Contribuição para a avaliação de hipertensão pulmonar em cães com doença mixomatosa da válvula mitral.** 2016. 100 f. Dissertação (Mestrado) – Universidade de Lisboa, Lisboa, 2016.

GIRARD, C.; HÉLIE, P.; ODIN, M. Intrapericardial neoplasia in dogs. **Journal of Veterinary Diagnostic Investigation**, v. 11, n. 1, p. 73-78, 1999. doi: 10.1177/104063879901100112.

MARTINELLI, E.; LOCATELLI, C.; BASSIS, S.; CROSARA, S.; PALTRINIERI, S.; SCARPA, S.; SPALLA, I.; ZANABONI, A. M.; QUINTAVALLA, C.; BRAMBILLA, P. Preliminary investigation of cardiovascular-renal disorders in dogs with chronic mitral valve disease. **Journal of Veterinary Internal Medicine**, v. 30, n. 5, p. 1612-1618, 2016. doi: 10.1111/jvim.14524.

NELSON, R. W.; COUTO, C. G. **Medicina interna de pequenos animais.** 4. ed. Rio de Janeiro: Elsevier, 2010. 1054 p.

PALACIO, M. J. F.; LÓPEZ, J. T.; DEL RÍO, A. B.; ALCARAZ, J. S.; PALLARÉS, F. J.; MARTINEZ, C. M. Left ventricular outflow tract obstruction secondary to hemangiosarcoma in a dog. **Journal of Veterinary Internal Medicine**, v. 20, n. 3, p. 687-690, 2006. doi: 10.1111/j.1939-1676.2006.tb02916.x.

REYNOLDS, C. A.; BROWN, D. C.; RUSH, J. E.; FOX, P. R.; NGUYENBA, T. P.; LEHMKUHL, L. B.; GORDON, S. G.; KELLIHAN, H. B.; STEPIEN, R. L.; LEFBOM, B. K.; MEIER, C. K.; OYAMA, M. A. Prediction of first onset of congestive heart failure in dogs with degenerative mitral valve disease: the PREDICT cohort study. **Journal of Veterinary Cardiology**, v. 14 n. 1, p. 193-202, 2012. doi: 10.1016/j.jvc.2012.01.008.

RUTHERFORD, L.; STELL, A.; SMITH, K.; KULENDRA, N. Hemothorax in three dogs with intrathoracic extracardiac hemangiosarcoma. **Journal of the American Animal Hospital Association**, v. 52, n. 5, p. 325-329, 2016. doi: 10.5326/JAAHA-MS-6362.

VERBEKE, F.; BINST, D.; STEGEN, L.; WAELBERS, T.; DE ROOSTER, H.; VAN GOETHEM, B. Total venous inflow occlusion and pericardial auto-graft reconstruction for right atrial hemangiosarcoma resection in a dog. **Canadian Veterinary Journal**, v. 53, n. 10, p. 1114-1118, 2012.

WARMAN, S. M.; MCGREGOR, R.; FEWS, D.; FERASIN, L. Congestive heart failure caused by intracardiac tumors in two dogs. **Journal of Small Animal Practice**, v. 47, n. 8, p. 480-483, 2006. doi: 10.1111/j.1748-5827.2006.00149.x.

WEISSE, C.; SOARES, N.; BEAL, M. W.; STEFFEY, M. A.; DROBATZ, K. J.; HENRY, C. J. Survival times in dogs with right atrial hemangiosarcoma treated by means of surgical resection with or without adjuvant chemotherapy: 23 cases (1986-2000). **Journal of the American Veterinary Medical Association**, v. 226, n. 4, p. 575-579, 2005. doi: 10.2460/javma.2005.226.575.