

# Detection of chicken anemia virus and infectious bursal disease virus co-infection in broilers

## *Detecção do vírus da anemia das galinhas em coinfeção com o vírus doença infecciosa bursal em frangos*

Jorge Luiz CHACÓN<sup>1</sup>; Eliana Ottati NOGUEIRA<sup>1</sup>; Liana BRENTANO<sup>2</sup>; Cleide R. GOMES<sup>1</sup>; Claudete Serrano ASTOLFI-FERREIRA<sup>1</sup>; Laura VILLARREAL<sup>1</sup>; Antonio José Piantino FERREIRA<sup>1</sup>

<sup>1</sup>Department of Pathology of College of Veterinary Medicine, University of São Paulo, São Paulo-SP, Brazil

<sup>2</sup>EMBRAPA Suínos e Aves, Concórdia-SC, Brazil

### Abstract

This survey aimed to investigate chicken anemia virus (CAV) in broilers flocks experimenting retarded growth and increasing mortality since the fourth day of age. Clinically, chickens presented depression, paleness, depigmentation and retarded growth. At necropsy, chickens presented CAV-compatible lesions. Samples from liver, spleen and thymus were tested by PCR for a 675-bp fragment of the CAV VP-1 gene, and all tested samples were positive. Serological and molecular techniques did not detect other pathogens, such as adenovirus, reovirus, astrovirus, infectious bursal disease and avian infectious bronchitis virus. These results showed that chicken anemia virus (CAV) may occur since the first few days of life in broilers - a fact not as yet reported -, associated with high pathogenic Infectious Bursal Disease Virus (IBDV) vaccine strain may induce a persistent growth retarded for several weeks in broilers.

**Keywords:** Chicken. Chicken Anemia Virus. Infectious Bursal Disease Virus. Coinfection. PCR.

### Resumo

Este estudo investigou a manifestação do vírus da Anemia Infecciosa das Aves (VAIA) em lotes de frangos que apresentavam retardo no crescimento e aumento da mortalidade observado a partir do quarto dia de idade. Clinicamente, as aves apresentavam depressão, palidez, despigmentação e retardo de crescimento. À necropsia, as aves apresentavam lesões compatíveis com a infecção pelo vírus da Anemia infecciosa das aves (VAIA). Amostras de fígado, baço e timo foram examinadas por PCR que amplifica um fragmento de 675 pb do gene VP-1 do VAIA. Todos os órgãos examinados foram positivos para o vírus da Anemia Infecciosa das Aves. Os demais patógenos, como adenovírus, reovírus, astrovírus, vírus da doença infecciosa bursal e coronavírus aviário não foram detectados pelas diferentes técnicas laboratoriais, como sorologia, PCR ou PAGE. Os resultados mostraram que o vírus da Anemia Infecciosa das Aves (VAIA) pode manifestar-se clinicamente nos primeiros dias de vida dos frangos - um fato ainda não reportado - associado ao vírus vacinal da doença infecciosa bursal (DIB) cepa forte pode induzir um persistente retardo de crescimento, por várias semanas, em frangos.

**Palavras-chave:** Galinha. Vírus da anemia das aves. Doença infecciosa bursal. Coinfeção. PCR.

## Introduction

Chicken Anemia Virus (CAV) is characterized by aplastic anemia and lymphoid depletion leading to thymus atrophy, bone marrow aplasia, low hematocrit values and retarded growth in chickens usually less than six-weeks old<sup>1,2,3,4</sup>. The genome of CAV consists of a single-stranded circular DNA<sup>5</sup>.

The clinical disease mainly occurs by vertical transmission, when breeder hens not previously exposed to CAV, and therefore not immune, become infected by this virus, in the laying period. The verti-

cally infected progeny develops the disease at about two weeks of age<sup>6</sup>.

As a result of lymphoid depletion, which produces immunodepression, CAV is often complicated by

### Correspondence to:

Prof. Antonio José Piantino Ferreira

Department of Pathology, College of Veterinary Medicine, University of São Paulo

Av. Prof. Dr. Orlando Marques de Paiva, 87, CEP 05508-270, São Paulo, SP.

e-mail: ajpferr@usp.br

Received: 01/08/2008

Approved: 04/03/2010

concomitant infections (viral, bacterial and fungal), mainly due to other immunodepressive viruses such as infectious bursal disease virus (IBDV), and impaired vaccine responses. Thus, CAV is regarded as an economically important disease because of the high losses from increased mortality, carcasses condemnations due to secondary bacterial infections, cost of medication and poor flock performance<sup>1,2,4,7,8</sup>.

Viral isolation can be carried out in MDCC-MSB1 cells or *in vivo*, in specific-pathogen-free (SPF) chickens, but it is both laborious and time-consuming. Polymerase chain reaction (PCR) has a high sensitivity for detecting DNA of CAV in tissue and blood samples. In addition to being fast, PCR allows further DNA analyses, such as restriction fragment length polymorphisms (RFLP) and DNA sequencing<sup>7,8</sup>. The gene that codes for VP1 viral protein – the major capsid protein inducing a major role in the induction of neutralizing antibodies and, for this reason, the gene that codes for this protein is quite useful in CAV detection by PCR<sup>5</sup>.

The objective of the present study was to describe an outbreak of CAV associated with high pathogenic IBDV vaccine strain may induce a persistent a growth retarded for several weeks in broilers.

## Material and Method

### Case history and collection of clinical samples.

For over a year, a commercial broiler farm located in São Paulo State (Brazil), with a multiage rearing system, had flocks showing clinical signs as depression, low weight gain, lack of body weight uniformity, increased mortality (up to 8%) and high culling rate (5%), starting in the fourth day of age. Besides, a high percentage of chickens (approximately 25%) presented paleness and somnolence. All flocks presented a decrease of 50% in the expected weight at the second week of age, and of 8% at the sixth week of age. Broilers were vaccinated against Marek's Disease

(HVT strain) on the first day post hatching and with the H120 strain against infectious bronchitis (IB) and against IBD with a mild intermediate strain at the seventh day of age and revaccinated with an intermediate-plus strain at the 14th day of age from CAV non-vaccinated breeders.

**Necropsy examination.** Twenty-four to 28-days-old broilers from four flocks (six chickens/flock) were euthanized by cervical dislocation and submitted to necropsy examination. Samples of thymus, spleen, bone marrow, liver, brain and faeces were obtained for serological and PCR diagnosis.

**Histopathology.** Thymus, bursa, trachea and lung tissue samples were collected at necropsy and fixed in 10% buffered formalin. The tissues were embedded in paraffin, sectioned and stained with hematoxylin and eosin (H&E).

**Serology.** Serum samples were collected from twenty 48-day-old broilers from different flocks and tested for antibodies against CAV, infectious bronchitis virus (IBV) and infectious bursal disease virus (IBDV) by commercial ELISA kits (Idexx™, Maine, USA).

**Polyacrilamide Gel Electrophoresis (PAGE).** At necropsy, fecal samples from 24 - 28-days-old birds were collected, pooled, and submitted for reovirus and rotavirus detection. Each pool consisted of fecal samples from six birds randomly selected per flock. The analysis was conducted by dsRNA extractions and PAGE according to the procedures described by Herring et al<sup>9</sup>.

**Polymerase chain reaction (PCR).** Total RNA was extracted with TRIzol reagent (Invitrogen™) according to the manufacturer's instructions. Total DNA was extracted as described by Chomczynski<sup>10</sup>. Samples of thymus, spleen, bone marrow, liver, brain and faeces were collected and submitted to PCR testing for adenovirus<sup>11</sup>, astrovirus<sup>12</sup>, CAV<sup>13</sup> and avian coronavirus<sup>14</sup>. CAV was surveyed by a PCR aimed to amplify a 675-bp fragment of the VP1 protein gene<sup>13</sup>. Positive

controls for the PCRs were as follows: Cux-1 strain (CAV) supplied by L. Brentano; H120 strain (IBV) gently supplied by Laboratório Biovet S. A. (Vargem Grande Paulista, SP, Brazil), Adenovirus VR-829 type 3 Tripton strain obtained from ATCC and a turkey astrovirus field strain isolated in the Laboratory of Avian Pathology – Department of Pathology, FMVZ - USP. Ultra-pure water was used as negative control. PCR products were detected by electrophoresis in 1.5% agarose gel stained with 0.5 µg/ml ethidium bromide, and examined under ultraviolet light.

## Results

Macroscopic lesions included general paleness, thymus and bursa atrophy, red bone marrow and petechial hemorrhages in the thymus, thighs and legs.

Histologically, the thymus showed a predominance of lymphoid cells in the medulla and severe lymphoid depletion in the cortex. The bursa presented mild lymphoid depletion and decreased follicle size.

Normal hematocrit values in chickens range from 29% to 32%, and hematocrit values lower than 27% are indicative of anemia. The 28-days-old birds examined presented hematocrit values between 14% and 24%, with an average value of 19%, indicating the occurrence of anemia.

High antibody titers against CAV were found [geometric mean titer (GMT): 1903 – 2174]. Low antibody titer with coefficient of variation (C.V.) were found against IBV (GMT): 138 – 490 and CV: 56 – 77%) and IBDV (GMT: 281 – 873 and CV: 70 – 82).

Reovirus, rotavirus, adenovirus, astrovirus and coronavirus were not detected in any of the samples by PCR or PAGE, excepted for CAV, which was detected in all samples examined by PCR (Figure 1). All reference strains resulted in the expected fragments, whereas no bands were found in the reactions corresponding to negative control.

CAV detection by PCR indicates that the broilers had had viral infection, which is supported by se-

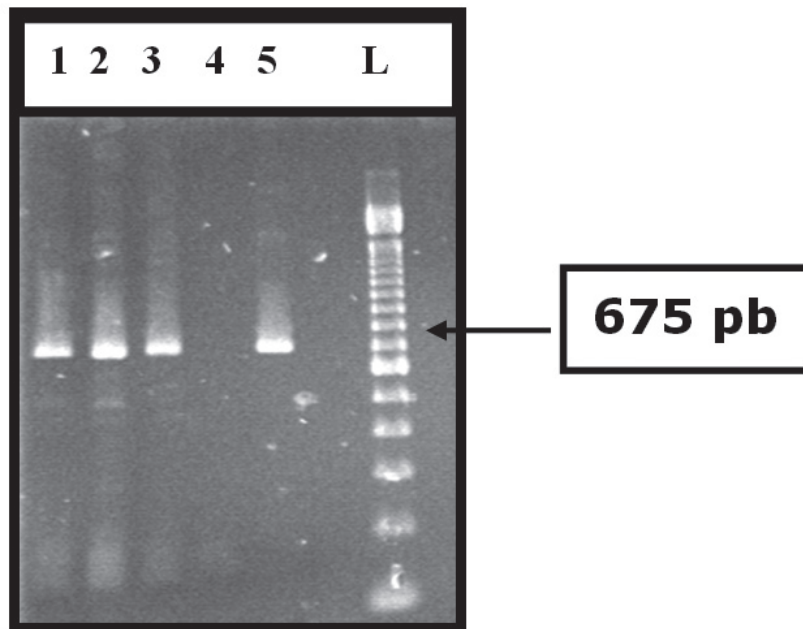


Figure 1 - Agarose gel showing PCR product from amplification of different organs samples, as described: 1 = thymus; 2 = spleen; 3 = bone marrow; 4 = negative control; 5 = positive control (CAV reference strain), L = 100-bp DNA ladder

roconversion at 48<sup>th</sup> day of age. In this survey, other pathogens – all able to produce similar clinical manifestations in chickens - were not found.

## Discussion

Clinical manifestation of CAV may be a consequence of vertical transmission, or infection, between 1-4 days of age. Usually, birds present depression, retarded weight gain and anemia with low hematocrit values since the twelfth day of age<sup>4,6,7,15</sup>. In the case reported herein, CAV infection could have resulted from vertical transmission, due to the early start of the outbreak and also to the fact that the surveyed flocks had come from non-vaccinated breeders. The horizontal spread might have occurred in the multi-age broiler enterprise. The vertical transmission might have been blocked in subsequent flocks after the vaccination of breeders, as indicated by absence of clinical signs in the progenies.

In experimental infections, anemia and distinct histologic lesions can first be detected eight days after parenteral inoculation of CAV. Clinical signs usually develop after 10 – 14 days, and mortality starts at 12 – 14 days after inoculation<sup>16</sup>. Nonetheless, in the surveyed farm, clinical signs began at earlier ages, such as the fourth day of age, which is uncommon for CAV. Interestingly, Ledesma et al.<sup>17</sup> inoculated field CAV in SPF chicks and could not reproduce the clinical disease, but did find CAV-specific lesions, suggesting that the findings were due to strains with different degrees of pathogenicity.

Since the beginning of the outbreak in this farm, a survey for micotoxins was carried out in the feed given to the birds, but the results showed absence of chemical, physical or microbiological risks (data not shown), according to the production data obtained from company. On the other hand, experimental and field infections with Marek's disease virus produce mononuclear infiltrations in nerves and other organs after two weeks,

and clinical signs of the disease were not observed before the third to fourth week of age<sup>18</sup>. According to this information, toxic processes and infection by Marek's disease virus were not involved in this case.

Surviving chicks completely recover from depression and anemia by 20 – 28 days after infection<sup>19</sup>, although retarded growth and increased mortality may persist for more time. CAV produces lymphoid depletion leading to immunodepression, which can allow opportunistic infections, poor response to vaccination and increased problems with IBDV<sup>5</sup>.

Intermediate-plus or high-pathogenic (called "hot") IBDV vaccine strain produces a more severe immunodepressive effect, which can induce a clinical disease if the birds have their immunological status compromised<sup>15</sup>. Furthermore, it is known that CAV produces immunodepression that affects the response to infectious bursal vaccine<sup>1,4,5</sup>. Microscopic lesions found in the birds studied herein are compatible with those described in cases of CAV-infection, such as severe lymphoid depletion in the thymus cortex. In the bursa, mild to moderate lymphoid depletion were found, which might be a consequence of infection with low pathogenicity field strains, or with high residual pathogenic IBDV vaccine strains<sup>20</sup>. Considering that serological evidences obtained by ELISA for IBDV did not indicate contact with field strains of this virus, the histopathologic lesions observed in the bursa may be attributed to high-pathogenic IBDV vaccine strain used in the farm.

The association of microscopic lesions with serological findings suggests that CAV symptoms here described may have been complicated by infection with an intermediate plus IBD vaccine strain administered at fourteenth day of age. In addition, clinical signs of the disease can suggest that started prior to IBDV vaccination, suggesting that CAV was the first and main etiologic agent of the disease found in the surveyed flocks.

CAV was detected in the examined birds, but early presentation of clinical symptoms, as well as absence of some CAV classic lesions, such as bone marrow aplasia, suggest that this particular CAV strain may be a non-classical one. Studies on experimental infection in SPF chicks with the CAV strains involved in this case may indicate the virulence degree of this virus, as well as its role as unique pathogen cause of clinical disease.

Clinical infectious anemia has been diagnosed in the fourth day of age, possibly resulting from a coinfection of vertical CAV and a “hot” IBDV vaccine strain.

As a conclusion, CAV may occur since the fourth day of age in broilers, and symptoms may be complicated by IBDV vaccination, especially when an intermediate plus, or a high-pathogenic (“hot”) IBDV-vaccine strain is used.

## Acknowledgments

The authors are grateful to FAPESP (Fundação de Amparo à Pesquisa do Estado de São Paulo) for financial support – Grant nº 00/09901-0.

## References

- BRENTANO, L.; MORAES, N.; WENTZ, I.; CHANDRATILLEKE, D.; SCHAT, K. Isolation and identification of Chicken Infectious Anemia Virus in Brazil. *Avian Diseases*, v. 35, p. 793-800, 1991.
- BUSCAGLIA, C.; NERVI, P. Identification of chicken infectious anemia isolation of the virus and reproduction of the disease in Argentina. *Avian Pathology*, v. 23, p. 297-304, 1994.
- ENGSTROM, B.; LUTTMAN, M. Blue wing disease of chickens: signs, pathology and natural transmission. *Avian Pathology*, v. 13, p. 1-12, 1984.
- HAGOOD, L. T.; KELLY, T. F.; WRIGHT, J. C.; HOERR, F. F. Evaluation of chickens infectious anemia virus and associated risk factors with diseases and production losses in broilers. *Avian Diseases*, v. 44, p. 803-808, 2001.
- SCHAT, K. A. Chicken infectious anemia. In: SAIF, Y. M.; BARNES, H. J.; GLISSON, J. R.; FADLY, A. M.; MCDOUGALD, L. R.; SWAYNE, D. E. (Ed.). *Disease of poultry*. 11. ed. Ames: Iowa State University, 2003. p. 182-201.
- MCILROY, S. G.; MCNULTY, M. S.; BRUCE, D. W.; SMYTH, J. A.; GOODALL, E. A.; ALCORN, M. J. Economic effects of clinical Chicken anemia agent infection on profitable broiler production. *Avian Diseases*, v. 36, p. 566-574, 1992.
- ROZYPAL, T. L.; SKEELES, J. K.; DASH, J. K.; ANDERSON, E. J.; BEASLEY, J. N. Identification and partial characterization of Arkansas isolates of chicken anemia virus. *Avian Diseases*, v. 41, p. 610-616, 1997.
- ZHOU, W.; SHEN, B.; YANG, B.; HAN, S.; WEI, L.; XIAO, B.; ZHOU, J. Isolation and identification of chicken infectious anemia virus in China. *Avian Diseases*, v. 41, p. 361-364, 1997.
- HERRING, A. J.; INGLIS, N. F.; OJHEH, C. K.; SNODGRASS, D. R.; MENZIES, J. D. Rapid diagnosis of rotavirus infection by direct detection of viral nucleic acid in silver-stained polyacrylamide gels. *Journal of Clinical Microbiology*, v. 16, p. 473-477, 1982.
- CHOMCZYNSKI, P. A. A reagent for the single-step simultaneous isolation of RNA, DNA and protein from the cell and tissues samples. *Biotechniques*, v. 15, p. 532-537, 1993.
- XIE, Z.; FADL, A. A.; GIRSHICK, T.; KHAN, M. I. Detection of avian adenovirus by polymerase chain reaction. *Avian Diseases*, v. 43, p. 98-105, 1999.
- KOCI, M. D.; SEAL, B. S.; SCHULTZ-CHERRY, S. Development of a RT-PCR diagnostic test for an avian astrovirus. *Journal of Virological Methods*, v. 90, p. 79-83, 2000.
- TODD, D.; MAWHINNEY, K. A.; MCNULTY, S. Detection and differentiation of chicken anemia virus isolates by using the polymerase chain reaction. *Journal of Clinical Microbiology*, v. 30, p. 1661-1666, 1992.
- CAVANAGH, D.; MAWDITT, K.; WELCHMAN, D. B.; BRITTON, P.; GOUGH, R. E. Coronaviruses from pheasants (*Phasianus colchicus*) are genetically closely related to coronaviruses of domestic fowl (infectious bronchitis virus) and turkeys. *Avian Pathology*, v. 31, p. 81-93, 2002.
- SANDER, J.; WILLIAMS, R.; NOVAK, R.; RAGLAND, W. In situ hybridization on blood smears for diagnosis of chicken anemia virus in broilers breeder flocks. *Avian Diseases*, v. 41, p. 988-992, 1997.
- GORYO, M.; SUWA, T.; UMEMURA, T.; ITAKURA, C.; YAMASHIRO, S. Histopathology of chicks inoculated with chicken anemia agent (MSB1-TK5803 strain). *Avian Pathology*, v. 18, p. 73-89, 1989.
- LEDESMA, N.; FEHERVARI, A. T.; CASAUBON, M. T.; LUCIO, E.; RATZ, F. Chicken infectious anemia in México and serology survey. *Avian Diseases*, v. 45, p. 788-796, 2001.
- WITTER, R. L.; SCHAT, K. A. Marek's disease. In: SAIF, Y. M.; BARNES, H. J.; GLISSON, J. R.; FADLY, A. M.; MCDOUGALD, L. R.; SWAYNE, D. E. (Ed.). *Disease of poultry*. 11. ed. Ames: Iowa State University, 2003. p. 407-464.
- ROSENBERGER, J. K.; CLOUD, S. S. The effects of age, route of exposure, and coinfection with infectious bursal disease virus on the pathogenicity and transmissibility of chicken anemia agent (CAA). *Avian Diseases*, v. 33, p. 753-759, 1989.
- LUKERT, P. D.; SAIF, Y. M. Infectious bursal disease. In: SAIF, Y. M.; BARNES, H. J.; GLISSON, J. R.; FADLY, A. M.; MCDOUGALD, L. R.; SWAYNE, D. E. (Ed.). *Disease of poultry*. 11. ed. Ames: Iowa State University, 2003. p. 161-180.