

Distemper in Brazilian wild canidae and mustelidae: case report

Cinomose em canídeos e mustelídeos silvestres brasileiros: relato de caso

Alexandre Aparecido Mattos da Silva REGO¹; Eliana Reiko MATUSHIMA¹; Celso Martins PINTO²; Iara BIASIA³

CORRESPONDENCE TO:
Eliana Reiko Matushima
Departamento de Patologia
Faculdade de Medicina
Veterinária e Zootecnia da USP
Av. Prof. Dr. Orlando Marques
de Paiva, 87 - Cidade
Universitária Armando Salles de
Oliveira
055508-900 - São Paulo - Brasil
e-mail: ermatush@usp.br

1 - Departamento de Patologia
Faculdade de Medicina
Veterinária e Zootecnia da USP
- SP
2 - Zoológico Municipal de
Taboão da Serra. São Paulo.
SP
3 - Parque Ecológico Tietê

SUMMARY

It is reported a distemper outbreak among Brazilian wild animals from the following species: *Galictis vittata*, *Crisocyon brachyurus* and *Cerdocyon thous*, kept in Taboão de Serra City Zoo - SP - Brazil. Histopathological analyses showed the main lesions of the disease including inclusion bodies in different sites. Survival of the only animal that had been previously vaccinated distemper stresses the importance of profilactic measures to control the disease.

UNITERMS: distemper, canidae, mustelidae.

INTRODUCTION

Distemper outbreaks in captive wild animals have been reported before^{7,24}. The present work reports gross and histopathologic findings in six animals of a group of thirteen that died after displaying distemper symptomatology. Two species were involved in the analysis: *Galictis vittata* (grison), *Crisocyon brachyurus* (maned-wolf). The only surviving animal in the group, a *Cerdocyon thous* (crab-eating-fox), had been previously vaccinated.

MATERIAL AND METHOD

Postmortem examination was conducted at Municipal Zoo of Taboão da Serra, SP - Brazil. Tissue samples were collected and sent in 10% formalin to the Department of Pathology of the Faculdade de Medicina Veterinária e Zootecnia, Universidade de São Paulo, for histopathologic evaluation.

Formalin fixed tissue samples were processed according to routine histological techniques, sectioned at a thickness of 5 micrometers, and stained with Hematoxylin-Eosin. Sections were analyzed under light microscopy.

RESULTS

The three grison displayed the following alterations: sight hemorrhage of adrenal medulla; vacuolar degeneration and necrosis of kidney tubular cells; focal necrosis of gastric mucosa; atrophy of gallbladder epithelium with occasionally extensive necrosis and polymorphonuclear cells infiltrate; pneumonia, congestion; decrease of splenic white pulp and presence of

megacariocytes; hepatocyte vacuolar degeneration and necrosis, mainly around centrilobular venae. Amorphous and eosinophilic intracytoplasmic inclusions were also seen in cells from gastric and gallbladder mucosa. (Fig. 1).

In both maned-wolves the following histopathologic alterations were observed: depletion of splenic white pulp with rarefaction of germinal centers; hepatocytes with extensive vacuolar degeneration and necrosis, diffuse pneumonia with edema, congestion and hemorrhage of lungs; small intestine presenting, necrosis of the vortex of the vili and mixed inflammatory infiltration spreading to the lamina propria, mononuclear cells infiltrate was seen invading the lamina propria of gastric mucosa. Amorphous and eosinophilic intracytoplasmic inclusions were also seen in cells from gastric and small intestine epithelia (Fig. 2).

In the histopathologic analysis of the crab-eating-fox it was observed; severe parasitic pneumonia with mono and polymorphonuclear inflammatory cell infiltration. Intracytoplasmic amorphous eosinophilic structures suggesting inclusion bodies in alveolar epithelial cells were also observed (Fig. 3). Meninges showed intense hemorrhage and severe inflammatory infiltration with macrophage predominance; at the optical nerve strong hemorrhage, extensive necrosis area and strong inflammatory infiltrate of mono and polymorphonuclear cells were observed. It was also verified a glial cell proliferation and edema, in the nervous tissue, as suggested by interstitial space increase. Intracytoplasmic and intranuclear amorphous eosinophilic structures were also observed in glial cells and neurons (Fig. 4). Slight decrease of the white pulp of the spleen, slight nephritis and diffuse tubular necrosis as well as chronic focal hepatitis and hepatocyte vacuolar degeneration were observed.



Figura 1

Gallbladder. Distemper. Grison (*Galictis vittata*). Mucosal epithelium with intracytoplasmatic inclusion bodies (a). HE stain (x 650).

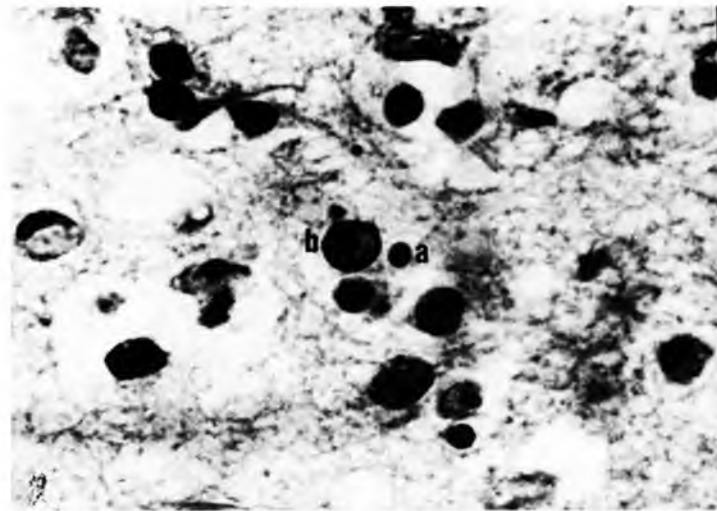


Figura 3

Brain. Distemper. Crab-eating fox (*Cerdocyon thous*). Intracytoplasmatic (a) and intranuclear (b) inclusion bodies in neurons. HE stain (x 1650).

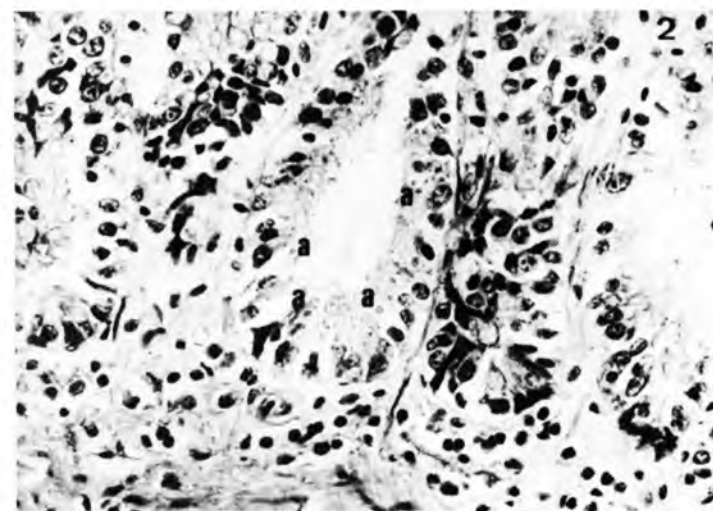


Figura 2

Small intestine. Distemper. Maned-wolf (*Crisocyon brachyurus*). Mucosal epithelium with intracytoplasmatic inclusion bodies (a). HE stain (x 650)




Figura 3

Lung. Distemper. Crab-eating fox (*Cerdocyon thous*). Alveolar epithelium with intracytoplasmatic inclusion bodies (a). HE stain (x 650).

DISCUSSION

Distemper has been reported in many animal species such as *Procyon lotor*², *Canis latrans*¹¹, *Mustela nigripes*¹⁰, *Vulpes macrotis nutica*¹⁶, *Stenella coeruleoalba*⁷, *Urocyon cinereoargenteus*⁹, *Phoca vitulina*¹ and *Martes martes*⁸.

Histopathologic changes observed in the lungs^{1,13,18} as well as spleen depletion of the white pulp¹, were previously reported. Intracytoplasmic and intranuclear inclusion bodies in the central nervous system associated with peracute, acute and subacute distemper cases in wild dogs in Greenland were reported by Blixenkrene-Moller⁵ (1983). Intracytoplasmic inclusion bodies in gut epithelium and gastric mucosa were described in domestic dogs^{10,19}. Gallbladder epithelium is also a common site for the occurrence of such intracellular bodies as observed by Bergman *et al.*² in *Phoca vitulina*, and also in the present report.

The incidence of the disease due to the virus among wild animal populations vary a lot (12-57%)^{9,11,14,16,21}. Guo *et al.*¹¹ (1986) determined the endemic character of the disease, with a prevailing occurrence of cases in the spring and autumn in Texas, USA.

The survival of the *Cerdocyon thous* of the present report, must have occurred due to its previous vaccination. Similar cases are reported by Jacobson; Kalias¹² (1988) and by Carter *et al.*⁴ (1992), the latter involving a trial with *Phoca vitulina*.

Distemper is found in free-living as well as in captive animals¹⁷. Wild animals⁵ and domestic canidae¹⁵ are among the possible vectors of the disease and are those which, in one way or another, maintain a synantropic relationship with captive animals and are able to infect them. Animals from Taboão da Serra Zoo and those reported here may have been infected that way.

RESUMO

Relatam-se cinco casos confirmados de Cinomose de um total de 13 óbitos de animais silvestres brasileiros das espécies *Galictis vittata*, *Crisocyon brachyurus* e *Cerdocyon thous*, mantidos em cativeiro no Zoológico Municipal de Taboão da Serra - SP - Brasil. À histopatologia observam-se as principais lesões da virose, inclusive a presença de corpúsculos de inclusão em diferentes localizações. A sobrevivência de um único indivíduo, vacinado contra Cinomose, reforça a importância desta medida profilática no controle da doença.

UNITERMOS: Cinomose; Canídeos; Multilídeos

REFERENCES

- 1- BAKER, J.R. The pathology of phocine distemper. **Science of the Total Environment**, v.11, n.1-2, p.1-7, 1992.
- 2- BERGMAN, A.; JASPLID, B.; SVENSON, B.M. Pathological findings indicative of distemper in European seals. **Veterinary Microbiology**, v.23, n.1-4, p.331-41, 1990.
- 3- BLIXENKRONE-MOLLER, M.; BOHM, J.; LUND, E. Outbreak of distemper among sledge dogs in North Greenland. **Dansk Veterinaestidsskrift**, v.72, n.9, p.488-97, 1989.
- 4- CARTER, S.D.; HUGHES, D.E.; TAYLOR, V.J.; BELL, S.C. Immune responses in common and grey seals during the seal epizootic. **Science of the Total Environment**, v.115, n.1-2, p.83-91, 1992.
- 5- CRANFIELD, M.R.; BARKER, L.K.; MEHREN, K.G.; RAPLEY, W.A. 1984. Canine distemper in wild raccoons (*Procyon lotor*) at the Metropolitan Toronto Zoo. **Canadian Veterinary Journal**, v.25, n.2, p.63-6, 1984.
- 6- DAVIDSON, W.R.; NETTLES, V.F.; HAYES, L.E.; HOWERTH, E.W.; COUVILION, C.E. 1992. Diseases diagnosed in grey foxes (*Urocyon cinereoargenteus*) from the southwestern United States. **Journal of Wildlife Diseases**, v.28, n.1, p.28-33, 1992.
- 7- DOMINGO, M.; FERRER, L.; PUMAROLA, M. Morbillivirus in dolphins. **Nature**, London, v.348, p.6296, 1990.
- 8- GEISEL, O. Diseases of beech martens (*Martens foina*) and pine martens (*Martes*) with special reference to pathological findings in organs. **Advances in Veterinary Medicine**, v.44, p.1-134, 1992.
- 9- GEISEL, E.M.; SCHULTZ, R.D.; RONGSTAD, O.J.; ANDERSON, D.E. Prevalence of antibodies against canine parvovirus and canine distemper virus in wild coyotes in southeastern Colorado. **Journal of Wildlife Diseases**, v.27, n.2, p.320-3, 1991.
- 10- GREENE, G.E. **Infectious diseases of the dog and cat**. Philadelphia, W.B. Saunders, 1990. p.234-5.
- 11- GUO, W.; EVERMANN, J.F.; FOREYT, W.J.; KNOWLTON, F.F.; WINDBERG, L.A. Canine distemper virus in coyotes: a serologic survey. **Journal of the American Veterinary Medical Association**, v.189, n.9, p.1099-100, 1986.
- 12- JACOBSON, E.R.; KOLIAS, G.V. **Exotic Animals**. New York, Churchill Livingstone, 1988. p.231-46.
- 13- KENNEDY, S.; SMYTH, J.A.; McCULLOUGH, S.J. Histopathologic and immunocytochemical studies of distemper in harbour porpoises. **Veterinary Pathology**, v.28, n.1, p.1-7, 1988.
- 14- KOLB, S.; SCHNABEL, H.; MIKULA, M. Distemper virus infection as cause of death of badgers in Austria. **Tierärztliche Praxis**, v.13, n.1, p.81-4, 1990.
- 15- KOLESNIK, V.S. Phocine distemper in Lake Baikal seals. **Khurnal Mikrobiologii i Epidemiologii i Immunologii**, v.9, p.52-6, 1990.
- 16- McCUE, P.M.; O'FARRELL, T.P. Serological survey for selected diseases in the endangered San Joaquin kit fox (*Vulpes macrotis mutica*). **Journal of Wildlife Diseases**, v.24, n.2, p.2740-81, 1988.
- 17- RATHONES, B.S.; KHERA, S.S. A survey of infectious and parasitic diseases of wild animals in captivity and free living state. **Indian Journal of Veterinary Pathology**, v.8, p.43-8, 1984.
- 18- SCHUMACKER, U.; HONRY, H.P.; HEIDEMANN, G.; SCHULTZ, W.; WELSCH, U. Histopathological findings in harbour seals (*Phoca vitulina*) found dead on the German North sea coast. **Journal of Comparative Pathology**, v.102, n.3, p.299-309.
- 19- SCOTT, F.W. **Infectious diseases**. New York, Churchill Livingstone, 1986. p.190-5.
- 20- WILLIAMS, E.S.; THORNE, E.T.; APPEL, M.J.G.; BELITSKY, D.W. Canine distemper in black-footed ferrets (*Mustela nigripes*) from Wyoming. **Journal of Wildlife Diseases**, v.24, n.3, p.385-98, 1988.
- 21- ZARNKE, R.L.; BALLARD, W.B. 1987. Serologic survey for selected microbial pathogens of wolves in Alaska, 1975-1982. **Journal of Wildlife Diseases**, v.23, n.1, p.77-85, 1987.

Recebido para publicação:
Aprovado para publicação: