

EXPERIMENTAL EVALUATION OF BRAIN SPECT USING d,1 -HMPAO^{99m}Tc IN DOGS. ANATOMO-PHYSIOLOGICAL IMPLICATIONS*

AVALIAÇÃO EXPERIMENTAL DE "SPECT" CEREBRAL MEDIANTE UTILIZAÇÃO DO d,1 - HMPAO ^{99m}Tc EM CÃES. CONSIDERAÇÕES ANATOMO-FISIOLÓGICAS

Benedicto Wladimir DE MARTIN¹; Teresinha Moraes Barreto ROCKMANN²; José MURADIAN³; Fabio Luiz Navarro MARQUES⁴; Débora Weinter de MORAES⁵; Carlos Alberto BUCHPIGUEL⁶; José Maria FERNANDES NETO⁷; Alípio Luiz DIAS NETO⁸

SUMMARY

Technetium-99m-d,1 hexamethylpropyleamine oxime (^{99m}Tc-HMPAO) is an important radiopharmaceutical used for both brain SPECT imaging and "in vitro" labelling of white blood cells. An increasing utilization of this radiopharmaceutical for studies of several neurologic and psychiatric diseases in humans, lead us to the preparation of the kits of HMPAO to be labelled with technetium-99m. This paper presents animal experimental studies with d,1-HMPAO^{99m}Tc prepared from lyophilized kits developed in our laboratories and also comparison to those commercially available. The brain scans have been done initially in rabbits, however better results were obtained with dogs. Six mongrel dogs clinically qualified as normals, were used in order to get scintigraphic brain pictures and washout curves of region of interest (ROIs). The value of experimental studies in animals and the considerable reduction in price of the so obtained radiopharmaceutical, have shown the viability of such procedure in the clinical practice as well in the veterinary clinic of small animals. By the other side, the perfusion of d,1-HMPAO^{99m}Tc showed that such a product concentrates at the same time in the cerebral area and nasal fossa, showing evidence of similar structures as the hemato encephalic barrier, also in the nasal area.

UNITERMS: Brain "SPECT"; ^{99m}Tc-HMPAO; Dog; Anatomico-physiological implication

INTRODUCTION

The d,1 - HMPAO^{99m}Tc (d,1-hexamethyl propyleamine oxime-^{99m}Tc) is a neutral-lipophilic chelate with a fast transfer through the hematoencephalic barrier that enable in this way tomographic (SPECT) studies of brain perfusion^{6,8,9}. This radiopharmaceutical has also been used with success in the "in vitro" labelling of white blood cells (WBC)⁷. Even with the widespread use in clinical research in several countries and commercially available since 1986^{1,2,3}, only by the end of 1990 the importance of the medical application of such a radiopharmaceutical has been evidential. From the synthesis of the HMPAO at our University⁵ we initiated studies in order to prepare ^{99m}Tc-HMPAO and also to demonstrate its feasibility in medical application⁸.

Most of the experimental studies with such a radiopharmaceutical were performed with hamsters and rabbits with smaller ROIs (Region of Interest) than those obtained with dogs and monkeys. From the comparison of brain pictures with such a radiopharmaceutical in hamsters, rabbits and dogs it was evidenced that better information is

obtained with dogs in the valuation of the above mentioned radiopharmaceutical.

JENKINS⁴ (1972) describes the anatomical behaviour of the meninges followings the sensitive nervus until their insertion in the receptive organs.

In the paper we studied brain scintigraphy in dogs through washout curves of selected ROIs, by the use of lyophilized kits of d,1 - HMPAO^{99m}Tc produced at the Centro de Medicina Nuclear, Universidade de São Paulo, with comparison of results of similar studies made with the imported kit.

MATERIAL AND METHOD

Animals

In this research, six (6) dogs have been used, four (4) males and two (2) females, weighing from 10 to 12 kilograms and clinically qualified as normal.

1 - Professor - Faculdade de Medicina Veterinária e Zootecnia da USP, São Paulo, Brasil

2 - PhD - Centro de Medicina Nuclear - Faculdade de Medicina da USP, São Paulo, Brasil

3 - PhD - Instituto de Química da USP, São Paulo, Brasil

4 - Chemist Centro de Medicina Nuclear, Faculdade de Medicina da USP, São Paulo, Brasil

5 - Pharmacist Centro de Medicina Nuclear, Faculdade de Medicina da USP, São Paulo, Brasil

6 - MD, PhD Centro de Medicina Nuclear, Faculdade de Medicina da USP, São Paulo, Brasil

7 - Master - Centro de Medicina Nuclear, Faculdade de Medicina da USP, São Paulo, Brasil

8 - PhD - Faculdade de Medicina da USP, São Paulo, Brasil

* Research performed at the Centro de Medicina Nuclear and Laboratório de Investigação Médica (LIM 44) from Hospital das Clínicas da Faculdade de Medicina da USP

Radiopharmaceutical

The d,l - HMPAO^{99m}Tc was prepared either with the kit produced at the Centro de Medicina Nuclear as well with the one commercially available.

After that, radiochemical quality control has been performed and the dose to be administered computed in a dose calibrator (296 MBq).

Equipments

All the washout curves as well the tomographic studies of brain perfusion (SPECT) were obtained with a Siemens ZLC-75 Orbiter scintillation camera interfaced to Siemens Microdelta Computer. The Victoreen model 34-056 dose calibrator was used in the determination of doses.

Anesthesia

Anesthesia has been performed by administration of 3% sodium pentobarbital at 15 mg/kg since xilazine chloridrate was injected previously at 1 mg/kg.

Tomographic Studies

Brain perfusion tomography was performed through the registration of 64 profiles of 30 seconds duration in a 360° circular orbit in the "step and shoot" mode, with the animals positioned in ventral decubitus.

Washout

The washout curves were obtained with the animals in the left lateral decubitus position. The dynamic study was performed in three groups of 20 images, the first with two seconds per frame and the others with one minute per frame.

Planar Images

After the completion of the tomographic procedure, planar pictures were obtained in order to evaluate the distribution of the radiopharmaceutical.

Comparison of Radiopharmaceuticals

In the tomographic study of brain perfusion (SPECT), a comparison of the distribution of radiopharmaceutical in two dogs, obtained with the kit produced at the Centro de Medicina Nuclear and the imported one, was performed. In the washout study performed in two animals, the curves obtained with the imported kit were compared to those with kits produced at the Centro de Medicina Nuclear. In the remaining animals only

washout curves obtained with the kits locally produced have been evaluated.

The washout curve from a ROI of a well defined cerebral area, has been compared from those of the nasal, to the one near the thyroid and also the cervical area, considered as background.

RESULTS

The d,l - HMPAO^{99m}Tc used in these experiments, either those obtained from imported kits, as well those from kits locally produced are equivalent concerning the biochemical properties.

The tomographic brain perfusion studies have been performed in the same dog with one week interval between examinations. The brain images so obtained showed that the d,l-HMPAO^{99m}Tc with the kit produced at the Centro de Medicina Nuclear was as efficient as the one commercially available (Fig. 3).

Identical conditions as those applied in SPECT procedure have been observed in the washout curve studies with 60 minutes duration. It was possible to see that all the curves are practically identical (Fig. 2).

The comparison of curves from several ROIs, as from the brain, nasal, thyroid and cervical areas, made through statistic analysis, showed that there was no difference in results with the kit produced at the Centro de Medicina Nuclear or with the imported one.

Through the systematic record of washout curves of d,l - HMPAO^{99m}Tc produced in our laboratory it was possible to foresee the utilization of such a technique in the detection of cerebral disorders in the veterinary clinic of small animals.

The presence of the radiopharmaceutical in the nasal fossa area in a concentration comparable to the one in the cerebral area will lead to new investigations, since the build-up curves in these areas starts practically at the same time (Fig. 1).

From the planar pictures of the distribution of the radiopharmaceutical it was not possible to see anything that can invalidate the results obtained by the SPECT technique.

DISCUSSION AND CONCLUSION

The d,l - HMPAO^{99m}Tc produced at the Centro de Medicina Nuclear offers the opportunity to develop perfusion research in dogs, since the quality of the products is comparable to the imported one.

By the other side, the perfusion of d,l - HMPAO^{99m}Tc showed that such a product concentrates at the same time in the cerebral area and nasal fossa, showing evidence of similar structures as the hemato encephalic barrier, also in the nasal area.

The same behaviour was previously described by JENKINS⁴ (1972).

From the results so obtained and due to the low cost of the locally produced radiopharmaceutical it's possible to foresee such a procedure in a routine basis of evaluation of cerebral disorder in small animals.

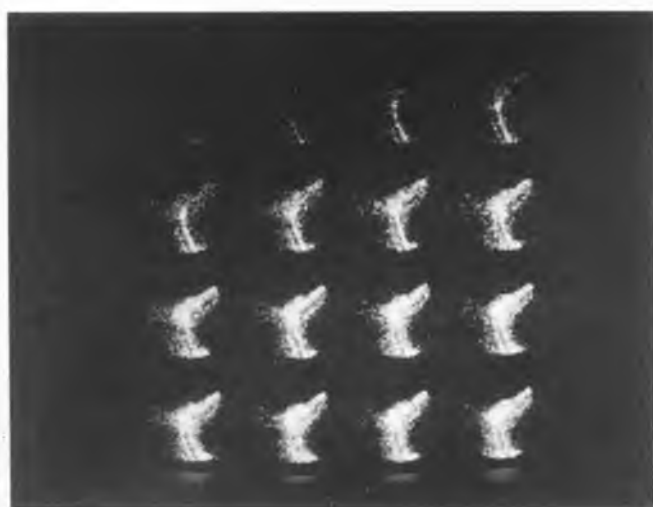


FIGURE 1

Cerebral blood flow showing the onset at the radiopharmaceutical at the same time in brain and nasal area.

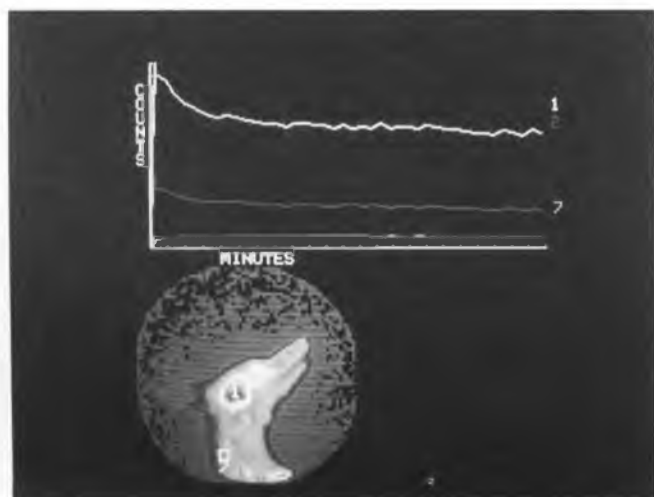


FIGURE 2

Analysis of washout curves in several ROIs showing the same behaviour of ROIs from the cerebral and nasal area.

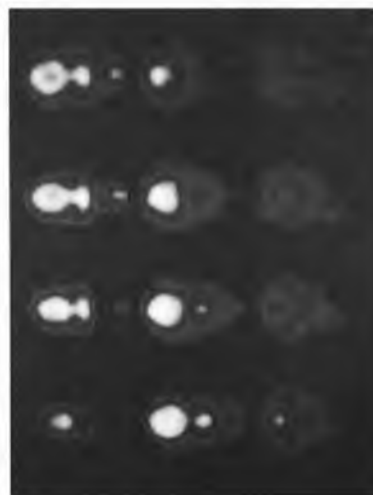
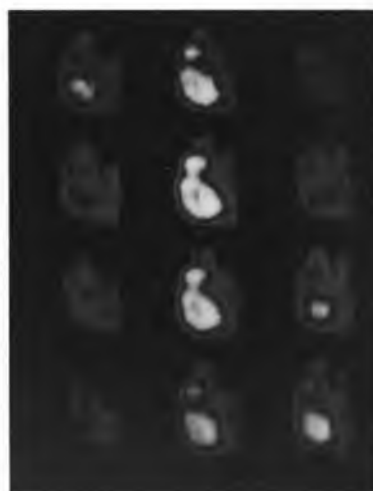
FIGURE 3

SPECT pictures: a transversal, b sagittal and c longitudinal sections, showing the localization of the radiopharmaceutical in the brain and nasal area.

RESUMO

O d,l - Hexametilpropileno oxima marcado com o tecnécio-99m(^{99m}Tc-HMPAO) é um importante radiofármaco usado tanto para imagens tomográficas cerebrais quanto na marcação "in vitro" de leucócitos. A crescente utilização deste radiofármaco no estudo de doenças neurológicas no homem levou-nos à obtenção de "kits" de HMPAO para ser marcado pelo tecnécio-99m. Neste trabalho apresentamos o estudo experimental efetuado com "kits" liofilizados de d,l - HMPAO^{99m}Tc desenvolvidos em nossos laboratórios, comparando inclusive com aqueles encontrados no comércio. As imagens cerebrais inicialmente foram feitas em coelhos, entretanto os melhores resultados foram obtidos em cães. Assim, selecionaram-se seis cães sem raça definida, considerados clinicamente normais para obtenção das imagens cintilográficas do cérebro e o "washout" das regiões de interesse (ROIs). Os estudos experimentais em animais e a considerável redução do custo do radiofármaco mostrou-nos a possibilidade da utilização destes exames na clínica veterinária, especialmente de pequenos animais. Por outro lado, a perfusão do d,l - HMPAO^{99m}Tc mostra que a concentração do radiofármaco se faz ao mesmo tempo na região do cérebro e nas fossas nasais, demonstrando a existência de estruturas iguais às da barreira hemo-encefálica nesta última região.

UNITERMOS: "SPECT" cerebral; ^{99m}Tc - HMPAO; Cão; Implicações Anátomo-fisiológicas

REFERENCES

- 01 - AMERSHAM INTERNATIONAL CERETEC, **Technetium^{99m} exametazine agent: for regional cerebral blood flow scintigraphy and in vitro^{99m}Tc Leucocyte labelling**. Buckinghamshire, England, Amersham International Plc, 1987.
- 02 - BALLINGER J.R.; REID, R.H.; GULENCHYN, K.Y. CIVIC Hospital, Ottawa. Radiochemical purity of ^{99m}Tc HMPAO: letters to the editor. *Journal of Nuclear Medicine*, v.29, p. 572-5, 1986.
- 03 - INTERNATIONAL ATOMIC ENERGY AGENCY. ^{99m}Tc - d,l - HMPAO. In: **Development of new radiopharmaceutical: final report of a research co-ordination meeting organized by the IAEA and held in Athens**, 12-15 September, 1989. Vienna, IAEA-TECDOC-532, p.33-4, 1989.
- 04 - JENKINS, T.W. **Functional mammalian neuroanatomy**. Philadelphia, Lea & Febiger, p.81-2, 1972.
- 05 - MURADIAN, J.; MARQUES, F.L.N. Síntese e separação do d,l - HMPAO para preparo de radiofármaco com Tecnécio^{99m} para uso médico. *Radiologia Brasileira*, v.25, n.2, p. 107-9, 1992.
- 06 - NEIRINCKX, R.D.; CANNING, L.R.; PIPER, I.M.; NOWOTNIK, D.P.; PICKETT, R.D.; HOLMES, R.A.; VOLKERT, W.A.; FOSTER, A.M.; WEISNER, P.S.; MARRIOTT, J.A.; CHAPLIN, S.B. Technetium-99m d,l-HMPAO: a new radiopharmaceutical for SPECT imaging of regional cerebral blood perfusion. *Journal of Nuclear Medicine*, v.29, p.191-202, 1986.
- 07 - PETERS, A.M.; DANPURE, H.J.; OSMAN, S.; HAWKER, R.I.; HERDENSON, B.L.; HODGSON, H.I.; KELLY, I.D.; NEIRINCKX, R.D.; LAVANDEN, J.P. Clinical experience with ^{99m}Tc- hexamethylpro-pyleanine oxime for labelling leukocytes and imaging inflammation. *Lancet*, v.2, p. 946-9, 1986.
- 08 - ROCKMANN, T.M.B.; MURADIAN, J.; MARQUES, F.L.N.; COELHO, I.J.C.; MORAES, D.W.; BUCHPIGUEL, C.A.; DE MARTIN, B.W.; CAMARGO, E.E.; DIAS NETO, A.L. Produção de conjuntos de reativos liofilizados para obtenção do ^{99m}Tc - HMPAO. In: CONGRESSO LATINO-AMERICANO DE ULTRASSONOGRRAFIA EM MEDICINA E BIOLOGIA, 5. *Anais*. Philadelphia, 1994. p. 236.
- 09 - SHARP, P.F.; SMITH, F.W.; GEMMELL, H.G.; LYALL, D.; EVANS, N.T.S.; GOZDANOVIC, D.; NEIRINCKX, R.D. Technetium-99m HM-PAO stereoisomers as potential agents for imaging regional cerebral blood flow: human volunteer studies. *Journal of Nuclear Medicine*, v.27, p. 171-7, 1986.

Recebido para publicação em 18/11/93
Aprovado para publicação em 10/06/94