

HIATAL HERNIA IN A DOG

Masao IWASAKI *
Benedicto Wladimir DE MARTIN **
José ALVARENGA ***
Mitika HAGIWARA ****

RFMV-A/8

IWASAKI, M.; DE MARTIN, B.W.; ALVARENGA, J.; HAGIWARA, M. *Hiatal hernia in a dog.* Rev. Fac. Med. vet. Zootec. Univ. S. Paulo, 14(1): 75 76, 1977.

SUMMARY: *Report about case of hiatal hernia in a female Dalmata 7 months old was presented. Data from clinical and radiological examinations were described; it was permitted conclude, through radiographes, that it was hiatus hernia, probably consequent to a congenital shortening of esophagus. This finding was confirmed by necrological examination.*

UNITERMS: *Radiography *; Hiatal hernia, dogs *.*

INTRODUCTION

Incidence of gastric hernias occurs more frequently because of anomalies of diaphragm (when esophageal hiatus presents abnormal largeness) and more rarely because of congenital shortening of esophagus³.

At veterinary literature it was met only one case of necrological finding without radiographic data; so, radiographies of this present report could not be compared^{1,2}.

CASE REPORT

By anamnesis, owner of female Dalmata 7 months old informed that its bad general nutritional conditions were because of vomits persisting during 30 days, and more recently, respiratory difficulty, also.

At clinical examination, animal showed prostration, cachexia, rectal temperature 36,7° C. Presence of sialism was neatly observed, with vomits constituted of digestive juices.

In spite of intense mixed dyspnoea, it was not possible detect any alteration, clinically.

Radiographic table showed at lateral face, presence of dense formation projecting from superior portion of diaphragmatic line to thorax, and that was not observed at ventral-dorsal position.

To elucidate radiographic table, it was preferred administer barium sulphate suspension, orally. Contrasted radiographies evidenced presence of part of stomach penetrating thorough esophageal hiatus, looking like a sac, projecting into thoracic region.

* Professor Assistente.

** Professor Livre-Docente.

*** Professor Assistente Doutor.

Departamento de Cirurgia e Obstetrícia da Faculdade de Medicina Veterinária e Zootecnia – USP.

**** Professor Assistente.

Departamento de Patologia e Clínica Médicas da Faculdade de Medicina Veterinária e Zootecnia da USP.

Also, by lateral radiography, it was observed a rectification of esophagus at thoracic portion, and a displacement of cardia to anterior limit of hernial sac. So, it was concluded be hiatus hernia, consequent to a congenital shortening of esophagus.

Death of the animal occurred soon after radiographic examination, because of its very bad general conditions.

Necrological examination, however, did not show, at simple observation, the formation radiographically detected.

But, after separation of collection esophagus-stomach-diaphragm, by means of auxiliary manoeuvre, it was seen, neatly,

projection of stomach through esophageal hiatus, to hernial sac.

DISCUSSION

In order to demonstrate rarity of this case, they were researched pathologies with radiographic diagnostic, during period from 1965 to 1975; they were found 439 cases of esophageal pathology, and 52 observations about traumatic diaphragmatic hernia.

Attention was awoke to radiographies observations do not be evidenced during necropsy; this suggests that rarity of this pathology id due to difficulty of observations "post-mortem".

RFMV-A/8

IWASAKI, M.; DE MARTIN, B.W.; ALVARENGA, J.; HAGIWARA, M. *Hernia de hiato em cão.* Rev. Fac. Med. vet. Zootec. Univ. S. Paulo, 14(1): 75-76, 1977.

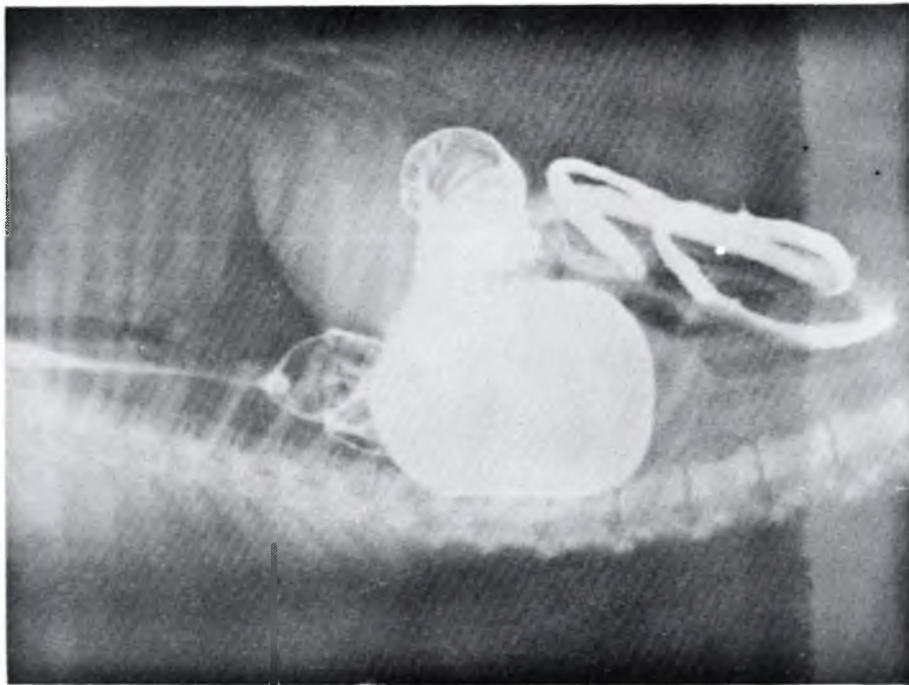
RESUMO: *Relato de um caso de hérnia de hiato em cão da raça Dalmata, fêmea, de 7 meses de idade. Os quadros clínico e radiológico, possibilitaram o diagnóstico de hérnia de hiato, provavelmente, em consequência a esôfago curto congênito.*

UNITERMOS: *Radiografia *; Hérnia de hiato, cães *.*

REFERÊNCIAS BIBLIOGRÁFICAS

- 1 - ARCHIBALD, J. *Canine Surgery.* California, American Veterinary Publication, 1965, p. 465.
- 2 - KLUTH, G.A. & KEMEA, T.L. *A case of hiatus hernia in a Boxer dog.* Vet. Rec., 76(18):501-2, 1964.
- 3 - ROBBINS, S.L. *Patologia com aplicação clínica.* Rio de Janeiro, Guanabara Koogan, 1965. p.679.

Recebido para publicação em 10-3-77
Aprovado para publicação em 3-8-77



Lateral lateral radiographic aspects after ingestion of contrast, showing gastric projection through esophageal hiatus.