

EXPERIMENTAL SELECTIVE BLOCKS OF THE INTERNODAL CONDUCTION PATHWAYS IN THE DOG

Paulo PEREIRA LEITE *
Vicente BORELLI **
Fabio Sandoli de BRITO ***
Renato ANDRETTO ****

RFMV-A. 33

PEREIRA LEITE, P.; BORELLI, V.; BRITO, F. S. DE; ANDRETTO, R. *Experimental selective blocks of the internodal conduction pathways in the dog.* Rev. Fac. Med. vet. Zootec. Univ. S. Paulo, 13(2):421-58, 1976.

SUMMARY: *Different aspects of the atrial activation were studied experimentally in the dog using conventional electrocardiographic methods.*

The importance as well as the functional characteristics of the internodal pathways (anterior, middle and posterior) were established by selective blocks of these connections.

The analysis of the results when compared to human electrocardiographic data allowed a better understanding of the atrial disturbances found in man.

UNITERMS: *Blocks,*; Internodal conduction*; Dogs.*

INTRODUCTION AND LITERATURE

Controversy regarding the spread of excitation of the sinus impulse has existed since the original descriptions of the sinoatrial and atrioventricular nodes.

The concept of apesialized conduction tissue in the heart had its origin in 1845 with the description by Purkinje^{1,2} of the cells which subsequently

bore his name. In 1893 HIS³ established the presence of a main A-V bundle, known as the Bundle of His. Later on, in 1906, TAWARA contributed with the now classical description of the A-V node followed by the identification of the sinoatrial node by KEITH & FLACK^{4,5} in 1907.

Some of these elements then were thought to be practically isolated since

* Médico do Serviço de Cirurgia Experimental do Hospital do Servidor Público do Estado de São Paulo.

** Professor Titular.

Departamento de Cirurgia e Obstetrícia da Faculdade de Medicina Veterinária e Zootecnia da USP.

*** Médico do Serviço de Cardiologia do Hospital do Servidor Público de São Paulo.

**** Professor Assistente Doutor.

Departamento de Cirurgia e Obstetrícia da Faculdade de Medicina Veterinária e Zootecnia da USP. Chefe Cirurgia Experimental do Hospital do Servidor Público Estadual de São Paulo.

no specialized connecting pathways between the sinoatrial and atrioventricular nodes were known.

In 1907 WENCKEBACH³² described a pathway formed by special "Purkinje-like" cells, which, starting at the base of the superior vena cava, descends the posterior wall of the right atrium, close to the interatrial septum, ending at A-V node.

In 1909 and 1910 THOREL^{29, 30} reported a specialized internodal tissue which went from the "crista terminalis" to the A-V node, reaching it at the height of the coronary sinus.

Although LEWIS¹¹ in 1910 believed that internodal conduction was due to a radial spread through the atrial musculature, EYSTER & MEEK^{5, 6} (1914/1916) and MEEK & EYSTER¹⁵ (1914) experimentally concluded that specific functional pathways existed between the sinus and the A-V nodes.

Correlating histological and physiological findings, BACHMANN³ (1916) reasserted the existence of specific internodal pathways, describing the via that bears his name and is situated at the junction of the superior vena cava with the right atrium extending to the left atrium.

TAKAYASU & DOSAWA^{25, 26} (1954), correlating anatomic and physiological findings, reported well defined connection tracts between the sinus and the A-V nodes in dogs. Several other authors as NISHII¹⁸ (1958/1959) DOSAWA¹⁹ (1959) and TATEISHI⁷² (1959) confirmed these findings.

The controversy, however, concerning the electrical stimulus propagation through preferential internodal pathways continued. Innumerable experimental or anatomic studies, as those of ROBB et al.²³ (1948) COPENHAUER & TRUEX¹ (1952), TRUEX³¹ (1961) and LEV¹³

(1960) simply denied or confirmed the presence of specialized internodal conduction pathways. JAMES¹⁰ (1963), however, settled the question through histological studies in human hearts of different ages, unequivocally demonstrating the following internodal conduction tracts:

- A) THE ANTERIOR INTERNODAL TRACT, starting at the anterior margin of the sinoatrial node, is formed by a interatrial branch — BACHMANN'S bundle — and another descending branch which accompanies the interatrial septum, ending at the crest of the A-V node.
- B) THE MIDDLE INTERNODAL TRACT, starting at the posterior margin of the sinoatrial node, passes above the inferior vena cava, descends the interatrial septum at the anterior margin of the "fossa ovalis", ending at the crest of the A-V node, together with the fibers of the anterior tract and the bundle described by WENCKEBACH³² (1907).
- C) THE POSTERIOR INTERNODAL TRACT, starting at the posterior margin of the sinoatrial node at the side of the middle tract, coursing along the crista terminalis, and, after enclosing the inferior vena cava, ends at the posterior margin of the A-V node, at the level of the coronary sinus. This tract corresponds to the specialized pathway described by THOREL²⁹ (1909).
- D) THE BY-PASS TRACT that connects the posterior tract to the distal portion of the A-V node, also receiving fibers from the anterior and middle tracts. These fibers may also reach the His bundle and are called paranodal fibers or JAMES' By pass, due to its electrophysiological significance.

MEREDITH & TITUS¹⁶ (1968) demonstrated histologically that the sinoatrial node is joined to the adjacent atrial myocardium by its entire border through cells presenting characteristics of both specialized and ordinary atrial myocardial cells, therefore being called transitional cells. These cells are concentrated in three areas, the most prominent emerging from the anterior margin of the sinoatrial node. Also confirming the internodal described tracts, the authors stressed the fact that although the pathways are not formed by cells possessing Purkinjelike characteristics, they present a distinctive histological differentiation when compared with the contractile atrial cells of the myocardium.

Parallel to these morphological studies, HORIBE⁹ (1961), YAMADA et col³¹ (1965), and WAGNER et col³³ (1966) demonstrated the functional existence of these preferential conduction pathways by means of experiments in which the stimulus propagation velocity and the action potential of the tract cells was measured.

While surgically removing the sinoatrial node, either partially, in 12 dogs, as part of an experiment, ANDRETTO et col.^{1,2} (1972/73) verified the derangement of some internodal conduction pathways by means of electrocardiographic studies.

Considering the monexistence of atrial activation studies observed by the conventional electrocardiogram, having particularly the electrical stimulus propagation by specific internodal conduction pathways in mind, we now try to investigate the morphological aspects of the ECG in dogs, which were experimentally submitted to selective temporary blocks of the intranodal conduction tracts, basing ourselves on the data found in specialized literature.

MATERIAL AND METHODS

1 — Experimental animals

Our results are based on electrocardiographic studies of 27 mongrel dogs, adults, 17 males and 10 females, obtained from the Faculdade de Medicina Veterinária e Zootecnia da Universidade de São Paulo.

2 — Grouping of the experimental animals

After having assessed that the dogs could be considered as clinically normal, they were divided at random into four groups. The first group held 12 animals (8 males and 4 females), the second 6 (4 males and 2 females) and the third 6 (3 males and 3 females) which had the internodal conduction pathways blocked, respectively, as follows: anterior middle and posterior; middle, anterior and posterior; posterior, anterior and middle. The remaining 3 animals (2 males and 1 female) formed a control group, being only submitted to incision and suture of the right atrial wall.

3 — Operation technique

The dogs were anesthetized with intravenously administered sodium pentobarbital, the dose being 30 mg/kg, followed by intubation with a cuff probe adapted to a Takaoka apparatus (model 840)

Maintaining the dogs under controlled ventilation and placing them on their left side with outstretched limbs on a thermic mattress, we proceeded with the thoracotomy at the level of the 4th right intercostal space. When the thoracic cavity was reached and the right lung removed we opened the pericardium, keeping the incision borders spread by means of cotton n.º 10 sutures.

Next we injected between the epicardium and the myocardium of the anterior, middle and posterior internodal

pathways to be blocked about 0,25 ml of local anesthetic of medium duration (± 6 hours) by means of a carpule syringe with a curved "Mizzy" needle. The selected areas to be blocked should be at least 1 cm distant of the sinoatrial node (Fig. 1). The anesthetic used was a parenteral marcaine solution at 5% without vasoconstrictor, corresponding to the bupivacaine hydrochloride (5 mg, q.s.p. 1 ml), attaining thus the temporary interruption of the cited pathways.

The three dogs of the control group were submitted to incision and continuous suture (4-0 marsilene thread) of the right atrial wall, starting near the opening of the caudal vena cava to the dihedral angle formed by the vena cava with the atrium, thus not interfering with the conduction course of the internodal pathways (Fig. 9).

Stimuli were applied to the sinus node by means of a "Mizzy" needle in order to assess the efficacy of the blocks.

At the end of the experiment, we closed the thoracic wall, inflating the lungs and approaching the ribs with crome catgut n.º 2, the muscular margins with catgut n.º 2-0 (continuous suture) and, finally the skin with n.º 10 cotton thread, separate stitches (double suture).

4 — Electrocardiographic records

The electrocardiographic studies were performed by means of a HEWLET — Pacard — 7 702 B direct recorder with two channels connected to a screen 7 803 B.

Before the surgery we recorded the standard and unipolar limb leads (DI, DII, DIII, aVR, aVL and aVF), of all animals, as well as the leads of the abdominal side of the thorax (precordial leads), the monitoring contacts of which were set up in a horizontal line above the ictus cordis. Thus, we designed T_1 , T_5 and T_{10} , the respective intersection points with the mean axillaries (right and left)

and with the longer axis of the sternum, considering the T_2 and T_4 points, situated at a distance between the extremes and T_{10} . (PEREIRA LEITE et col. ²¹ — 1972).

During surgery and after blocking each studied pathway, we recorded standard ECG leads and unipolar limb leads simultaneously with the intracavitary lead by means of a electrode catheter. This device was inserted into the right external vena jugularis, thus reaching the cranial vena cava so that its free end was situated under the area of the sinus node (*sulcus terminalis*).

R E S U L T S

The most significant electrocardiographic aspects observed during the selective blocks of the internodal conduction tracts are here presented separately divided into 3 groups according to the internodal conduction pathway which was initially blocked.

Group 1 — Anterior internodal tract

In 12 animals the following electrocardiographic alterations were recorded during consecutive blocks starting with the anterior internodal tract:

- 1 — Direction of the mean atrial activation vector (SAP) — Fig. 8). The SAP before the block of the anterior internodal pathway varied between $+30^\circ$ to $+90^\circ$ to the front, the average being 73° . After the selective block of the anterior internodal tract the SAP was situated between -20° and -90° parallel or backwards in relation to the frontal plane, the average being -31° ; there was thus a mean variation of 104° to the left and to the rear of the representative atrial activation vector (Fig. 2, 3, 5, 7).
- 2 — Cardiac rhythm after the selective block of the anterior internodal tract.

In all animals observed the cardiac rhythm remained sinusoidal with morphological alterations of the P wave mentioned above (Fig. 2, 3, 5, 7).

3 — Cardiac rhythm after successive blocks of the anterior, middle and posterior tract

By first interrupting the anterior internodal tract and then blocking the middle tract, junctional rhythm was produced in 4 dogs; in 7 other animals this rhythm only appeared after blocking the three pathways (Fig. 5, 7); in the remaining cases, by chronologically blocking the middle and the posterior pathways, the rhythm and the morphology of the P wave did not change, a fact observed after the initial block of the anterior tract. Among the 11 cases that produced junctional rhythm, 5 presented retrograde atrial activation (Fig. 7). In the remaining cases it was not possible to detect any indication of atrial depolarization, even means of a simultaneous intracavitary electrocardiogram; QRS complexes without a P wave were the rule (Fig. 5).

4 — Mechanical stimulation of the sinus node.

The mechanical stimulation of the sinoatrial node was performed, as explained in 5 dogs before the blocks. In all cases the response was considered positive represented by isolated sinus extrasystoles or successive groups of extrasystoles. After the initial block of the anterior internodal pathway, the mechanical stimulation continued producing positive responses and, in 4 cases, it also remained positive after blocking the middle internodal pathway. A negative response was only obtained after the selective block of the posterior

internodal pathway, coinciding with the appearance of the junctional rhythm (Figs. 3, 5). Mechanical stimulation did not produce any result in one animal only, immediately after having blocked the middle internodal pathway, coinciding with the onset of the junctional rhythm.

5 — Other electrocardiographic aspects.

Of the 12 studied animals, 7 did not demonstrate any significative electrocardiographic modifications besides those already mentioned, in 4, however, important morphological alterations of the QRS complex were observed coinciding with the performed blocks. In one case a short P-R interval was observed after having blocked the anterior and the middle internodal pathways (Fig. 7).

Group II — Middle internodal tract

The following electrocardiographic alterations were observed in 6 animals after consecutive blocks of the middle internodal pathway:

- 1 — Direction of the mean atrial activation vector ((SAP) — (Fig. 8C). In 3 dogs the direction of the SAP did not undergo an alteration (Fig. 6). In the other 3 there was a deflection to the right after having only blocked the middle internodal pathway, the direction being $+83^\circ$ before the interruption and $+105^\circ$ after it (Fig. 4).
- 2 — Cardiac rhythm after the selective block of the middle internodal tract.
In all studied animals sinus cardiac rhythm was observed (Figs. 4, 6).
- 3 — Cardiac rhythm after successive blocks of the middle, anterior and posterior tracts.

By interrupting the middle internodal tract, the block of the anterior internodal tract produced junctional rhythm in 3 animals (Fig. 6); in the remaining cases this rhythm could only be observed after also blocking the posterior internodal tract (Fig. 4).

With the onset of the junctional rhythm 2 animals presented retrograde atrial activation (Fig. 6), which disappeared by blocking the posterior internodal tract; the other 4 dogs did not display retrograde atrial activation once the junctional rhythm was produced (Fig. 4).

4 — Mechanical stimulation of the sinus node.

In the 5 cases observed the results were similar to those produced by the animals of group I, i.e. the result was positive until the onset of the junctional rhythm, becoming inefficient or negative with evidence of "sinusal extrasystoles" (Fig. 4, 6).

5 — Other electrocardiographic aspects.

In 2 cases morphological modifications of the QRS complex was noted after the interruption of the three pathways; in 1 animal the shortening of the P-R interval was observed due to the block of the middle and anterior internodal pathways (Fig. 4).

The 3 dogs mentioned in item 1 of this group, the SÂP of which did not change by selectively blocking the middle internodal pathway, demonstrated a similar SÂP reaction to the dogs of group 1 when interrupting the anterior internodal pathway, i.e. the SÂP deflected to the left and to the rear.

Group III — Posterior internodal tract

The following electrocardiographic data were obtained by consecutive blocks of the posterior internodal pathway:

1 — Direction of the mean activation vector (SÂP) — (Fig. 8D).

No alteration was actually observed of the SÂP vector while exclusively blocking the posterior internodal tract.

2 — Cardiac rhythm after the selective block of the posterior internodal tract.

In all studied animals the sinus rhythm was maintained after specific block of the posterior internodal tract.

3 — Cardiac rhythm after successive blocks of the posterior, anterior and middle tracts.

In 4 dogs junctional rhythm only occurred after interrupting the 3 pathways, and in 2 cases the block of the posterior and anterior pathways were sufficient to provoke a junctional rhythm.

In 5 cases, while observing junctional rhythm, no atrial activation was noted, i.e. QRS without a P wave. In the remaining case the junctional rhythm produced retrograde atrial activation which only disappeared with the final block of the middle internodal pathway.

4 — Mechanical stimulation of the sinus node.

Similar results were obtained to those in group II.

5 — Other electrocardiographic aspects.

In this group no alterations of the QRS complex nor of the P-R interval were noted.

In the 4 cases in which the selective blocking of the anterior and posterior internodal pathways did not produce junctional rhythm, the SÂP behaved as in group I, deflecting its vector to the left and upward.

Group IV — Control

The incision and suture of nearly the entire length of the right atrial wall

without derangement of the internodal conduction pathways did not produce alterations of the P wave observed while blocking these same pathways.

Global analysis of the results

Considering the sequence of the successive blocks of the internodal conduction pathways performed in the different groups, i.e.: group I — anterior, middle and posterior internodal tracts; group II — middle, anterior and posterior and posterior; group III — posterior, anterior and middle, we were able to observe that the most important alterations occurred while blocking the anterior and the middle internodal pathways.

Through the global analysis of the results obtained, a better anatomic and physiological understanding of the different studied pathways was possible, demonstrating that:

- 1 — Direction of the mean atrial activation vector (SAP).
In the 4 studied dogs the posterior internodal tract when initially blocked did not change the atrial activation; in 3 of the 6 dogs observed, the middle internodal pathway, when interrupted in the beginning, produced a SAP deflection to the right; the anterior internodal pathway, when initially blocked, in 12 cases of group I produced a deflection of the SAP to the left, the same occurring after interruptions without alteration of the SAP of the middle internodal pathway in 3 cases of group II, and the posterior internodal pathway in 4 cases of group III.
- 2 — Cardiac rhythm after initial block.
In all animals used the cardiac rhythm always remained sinus after the initial block of any of the studied pathways.
- 3 — Junctional rhythm.
Junctional rhythm was only pro-

duced after the selective blocking of the three pathways in 14 animals, corresponding to 7 of group I, 3 of group II and 4 of group III. In the remaining 10 dogs junctional rhythm only occurred while blocking two pathways, i.e. in 5 animals of group I (anterior and middle internodal tracts), in 3 of group II (middle and anterior internodal tracts) and in 2 of group III (posterior and anterior internodal tracts).

- 4 — Atrial activation in junctional rhythm.
In 24 animals with junctional rhythm 16 did not present atrial activation any more right after the onset of this rhythm; in the other 8, retrograde atrial activation was noted, 3 of which passed over to a junctional rhythm with absence of the P wave, after having blocked the third pathway (middle or posterior).
- 5 — Mechanical stimulation of the sinoatrial node.
In the studied dogs the response was always positive until the onset of junctional rhythm when it became negative.
- 6 — QRS complex.
In 6 cases, i.e. 4 dogs of group I and 2 of group II, morphological variations were observed, this when the anterior and middle internodal tracts were initially blocked.
- 7 — P-R interval.
In 2 cases the shortening of the P-R interval after blocking the anterior and the middle internodal tracts was noted, corresponding to 1 animal of group I and another of group II.

C O M M E N T S

The data obtained by selectively blocking the three internodal conduction

pathways, analysed by means of the conventional electrocardiogram, permitted to functionally confirm some of the anatomic concepts on one hand, while on the other hand to correlate certain electrocardiographic patterns with the blocking of the already mentioned pathways.^{22, 23.}

Thus we may say that the right atrial myocardium is constituted of three distinct areas, each one being activated by one of the internodal pathways.

The anterior internodal pathway stimulates part of the left wall of the right atrium (*facies auricularis*) and the left part of the interatrial septum. This activation process can be represented by a vector directed from right to left, from top to bottom and from the rear to the front (Fig. 8A). The middle internodal pathway basically activates part of the right wall (*facies atrialis*) of the right atrium and the middle part of the interatrial septum. This can be represented by a vector directed from right to left, from the front to the rear and practically parallel to the frontal plane (Fig. 8A). The posterior pathway activates part of the right wall (*facies atrialis*) of the right atrium and the right part of the interatrial septum, being represented by a vector directed from right to left, from the front to the rear, also approximately parallel to the frontal plane (Fig. 8A).

This vectorial concept enables us to understand the deflection to the left and backwards of the resulting atrial myocardium activation vector, when blocking the anterior internodal pathway. This fact was observed in 20 dogs (Fig. 2, 3, 5, 7), as well as the change of direction of the S₁P to the right and to the front (Fig. 8C), observed in 3 dogs (Fig. 4) after having blocked the middle internodal pathway. Finally, the absence of significative variations of the vectorial direction by initially impairing the posterior internodal pathway can also be explained by this concept (Fig. 8D).

By the extent and frequency of these electrocardiographic alterations we may assume that anterior internodal pathway is responsible for the activation of the larger part of the right atrial myocardium, followed by the middle internodal pathway, playing the posterior internodal pathway the least significant activation role. These findings are in entire accordance to the resulting rhythm data obtained by successively blocking the cited conduction pathways. Thus in 14 of the 24 studied animals junctional rhythm only occurred after blocking the three internodal pathways. This fact demonstrates the functional importance of all of them (Fig. 4, 5, 6).

Although the morphological aspect of the P wave was not changed in the cases where initial selective blocking of the middle or the posterior pathway was performed — suggesting thus an inactivity of the same their active if limited role was demonstrated by vectorial observation.

On the other hand the data obtained from 9 animals where the junctional rhythm appeared by interrupting the anterior and middle pathways (7 times) or the anterior and posterior pathways (2 times), led us to accept the presumable hypothesis of the functional nonexistence of the posterior internodal pathway in the first case, and the middle internodal pathway in the second.

The findings presently analysed reveal some informations that coincide with facts by us observed in previous studies, when experimentally removing the sinus node, partially and entirely in 12 canine hearts.^{1, 2}

Trying to assess the importance of the pathways, we thus believe that the following functional hierarchy can be established: the anterior internodal pathway, following the middle and finally the posterior internodal pathway.

The mechanical stimulation of the sinus node as performed unequivocally confirmed the efficacy of selective blocking, also proving the exclusiveness of the impulse propagation by the various internodal tracts.

This excitation was always inefficient when junctional rhythm was revealed through electrocardiographic tracing, proving the impossibility in these cases of the stimuli to reach the atrial myocardium (Fig. 3, 4, 5, 6).

The incision and the suture of right atrial wall, on the other hand, nearly including the entire extent of the *facies atrialis* (Fig. 9), excluding the conduction system of the internodal pathways, did not produce any alterations of the P wave observed with the interruption of the mentioned pathways (Fig. 10), and with the simple mechanical stimulation of the right atrial wall (Fig. 4). These findings corroborated the affirmations of MEREDITH & TITUS¹⁶, who histologically demonstrated there interatrial conduction pathways emerging from the sinus node represented by an accumulation of specialized cells, more concentrated at the anterior margin of this node, possibly confirming the greater importance of the anterior internodal tract, a fact by us now observed.

As to the modifications found in the QRS complex of 6 dogs (Fig. 4) which had their anterior and middle internodal pathways blocked, we presume that the stimulus reached the ventricular myocardium through JAMES' paranodal fibers¹⁰. These connection pathways found in some animals unite the posterior internodal pathway to the distal part of the atrio-ventricular node or directly to the His bundle trunk, rendering a varying propagation of the electrical impulse possible. This situation, which alters the equilibrium between the right and the left branches of the His bundle — occurring when

the impulse proceeds from the A-V node — might explain the ventricular complex deformations. Due to the fact that the paranodal connection fibers can also directly and at the ventricular mass, the shortening of the P-R interval by exclusion of the A-V node as propagation pathway of the stimulus could also be explained (Fig. 4, 7).

An interesting aspect concerning atrial activation was the absence of atrial depolarization, after the onset of the junctional rhythm, observed in the majority of the cases, i.e. in 16 of the 24 dogs examined (Fig. 4, 5). Since the blocks were performed near to the sinoatrial node, it would be logical to admit an inverse impulse conduction after the manifestation of the junctional rhythm, by means of the same internodal pathways, producing the retrograde P wave. The fact that this did not occur, in our opinion, indicates the presence of a one-way impulse direction in the internodal pathways, from the sinoatrial node to the A-V node, or a conduction block in the opposite direction.

We believe that many insights obtained from this study, as well as their interpretations, might be applied to human electrocardiography.

Thus it is of common knowledge that ectopic atrial rhythms, junction rhythms or simple morphological modifications of the P wave mainly occur in cardiac surgery which affects the interatrial septum.¹⁷ Basing ourselves on our experimental studies it is plausible to admit that the so called ectopic rhythms or the morphological variations of the P wave simply represent a block of one of the conduction tracts or of their pathway in the interatrial septum due to surgery.¹⁷ Specialized literature also mentions cases of abnormal atrial activity in patients who suffer from lipomatous hypertrophy of the interatrial septum⁷, where especially the anterior and the middle internodal pathways are

jeopardized, thus determining a SAP change with a negative P wave in the leads DII, DIII and aVF, being this fact similar to the situation when we blocked the cited pathways.

Another important aspect frequently described in studies referring to the sinus node disease is the occurrence of morphological alterations of the P wave, besides sinus bradycardia, sinoatrial blocks and sinus arrests.

Persons who suffer from sinus nodopathy frequently reveal electrocardiographic periods with slow rhythms and anomalous P waves considered up to now atrial ectopic escape rhythms resulting from a sinus node failure²⁴ (Figs. 11, 12). In our opinion these findings reveal bradycardiac sinoatrial rhythm reaching the atria in a failing manner, however, due to the interruption or to the impairment of one or two internodal conduction pathways. This fact is corroborated by the unaltered heard rate, when we compare the slow sinus rhythm with the one following the anomalous P wave (Fig. 11). In electrocardiography it is also not uncommon to observe the occurrence of anomalous P waves preceded by sinoatrial blocks, pointing to the possibility of an impairment of the last pathway used for sinoatrial conduction (Fig. 12). Thus a succession of similar situations to those found in atrioventricular blocks, of the right branch, afterwards by the proceed frequently by the interruption block of one of the fascicles of the left branch would finally lead, through the derangement of the last one, to the total atrioventricular block.

The results of our experiments compared with human electrocardiograms inserted in this work for elucidation, allow for a better understanding of the morphological alterations of the P wave. Thus, modifications of this wave, frequently mentioned in medical literature and classically known under ectopic

atrial rhythms, left atrial rhythm, sinoatrial conduction disturbances, wandering pacemaker and others^{20, 21}, would actually correspond to a normal sinus rhythm, however, activating the atrial myocardium in an anomalous manner due to the derangement of one or two internodal conduction pathways. Thus, from our point of view, the experimental changes observed in the morphology of the P wave, resulting from the selective interruptions of the internodal conduction pathways before the appearance of junctional rhythms would be identical to the modifications of the P wave frequently found in persons suffering from sinus nodopathy¹¹.

CONCLUSIONS

The data obtained in our experiments by selectively blocking the internodal conduction pathways, performed in 27 hearts of mongrel dogs, adults, 17 males and 10 females, allow us to reach the following conclusions:

- 1 — The internodal conduction pathways described anatomically were functionally confirmed by means of conventional electrocardiograms.
- 2 — The anterior internodal pathway, as to the functional aspect, was found to be the most important, followed by the middle and, finally, by the posterior internodal pathway.
- 3 — With the selective block of the anterior internodal pathway, the mean vector representing atrial activation (SAP) revealed average variation of 104° to the left and to the rear relation to the frontal plane.
- 4 — After the selective block of the middle internodal pathway, the direction of the mean atrial activation vector (SAP) did not change (50%) or deflected to the right in

relation to the frontal plane, passing from $+83^{\circ}$ to $+100^{\circ}$ (50%).

- 5 — No significative alteration was observed concerning the direction of the mean atrial activation vector (SAP) while selectively blocking the posterior internodal pathway, thus evidencing its small functional importance.
- 6 — In all studied animals the cardiac rhythm remained sinus after initially interrupting any of the internodal conduction pathways.
- 7 — The junctional rhythm generally appeared after blocking the three internodal conduction pathways (60%), revealing the importance of all pathways, also occurring, however, by deranging the anterior and the middle internodal pathways (40%), evidencing in these cases the small interference of the posterior internodal pathway.
- 8 — After the appearance of the junctional rhythm, due to the blocking of the internodal conduction pathways, observed in all studied animals, very often (66.7%) no retrograde atrial activation was noted, demonstrating a one-direction tendency.
- 9 — Mechanical stimulation of the sinoatrial node site always provoked positive responses (isolated extrasystoles or in successive groups) with the exception when the junctional rhythm occurred, proving that the studied pathways are the only ones to leave the sinoatrial node.
- 10 — By blocking experimentally the internodal conduction pathways, QRS complex sometimes (25.0%) revealed changes, while the shortening of the P-R interval was observed in 8.0% of the cases due to the impairment of the anterior and middle internodal pathways. This fact indicates the presence, in some cases, of connections between the posterior internodal pathway and the low portions of the junctional system.
- 11 — The incision and suture performed in the right atrial wall beyond the pathway of the internodal conduction tracts did not produce alterations of the mean atrial activation vector (SAP), observed by blocking the cited pathways, only revealing atrial lesion current.
- 12 — The alterations of the mean atrial experimental interruption of the activation vector (SAP) due to experimental interruption of the internodal conduction pathways coincide with human electrocardiographic data of patients who suffer from sinus nodopathy, pathology of the atrial myocardium, atria surgery and other atrial pathologies.



FIGURE 1 — Photography of the (right) faces atrialis of a canine heart in which of the right wall of the atrium and ventriculium was removed; the position of the anterior (A), middle (M) and posterior (P) internodal pathways are shown schematically, as well as the site (X) where they were blocked.

FIGURA 2

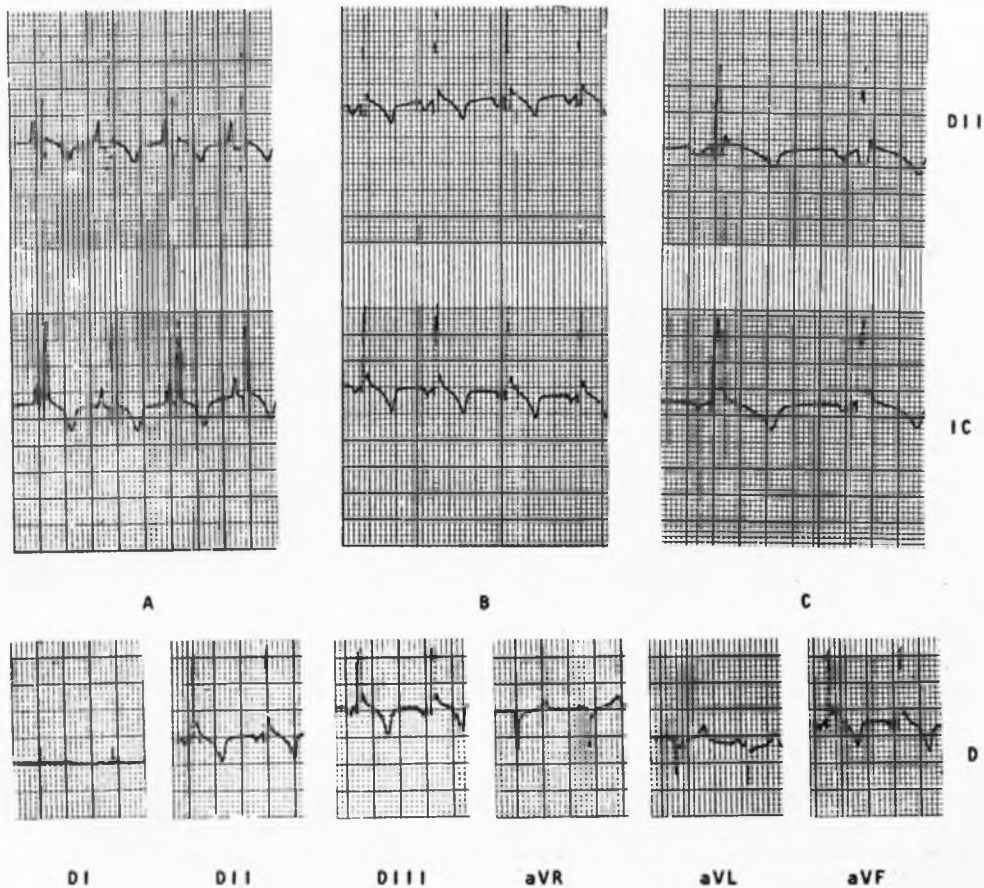


FIGURE 2 — Electrocardiograms showing SAP deflection to the left after the selective block of the anterior internodal tract

- A — Simultaneous intracavitary and DII leads before the selective block of the anterior internodal tract. P waves of high voltage.
- B, C — Simultaneous intracavitary and DII leads (vel. 25 and 50), after the selective block of the anterior internodal tract.
- D — Frontal plane leads (DI, DII, DIII, aVR, aVL, aVF) after the selective block of the anterior internodal tract.
Negative P waves in DII, DIII, aVF, the SAP being deflected to the left and upward (-75°).

FIGURE 3 — Electrocardiograms showing a SAP deflection to the left and to the rear after the selective block of the anterior internodal tract, demonstrating the sinoatrial conduction through other pathways after mechanical stimulation.

- A — Frontal plane leads (DI, DII, DIII, aVR, aVL, aVF) and T3 leads before the selective block of the anterior internodal tract.
SAP +65° forward and positive P wave in T3.
- B — Simultaneous intracavitary and DII leads (vel. 25/2N) before the selective block of the anterior internodal tract.
Positive P waves in DII and of the rS pattern in the intracavitary lead.
- C — Simultaneous intracavitary and DIII leads after the selective block of the anterior internodal tract.
Practically isoelectrical P waves in DII (—30°) and of the QS pattern in the intracavitary lead.
- D — Simultaneous intracavitary and T3 leads after the selective block of the anterior internodal tract.
Isoelectrical P waves in T3 (parallel to the frontal plane), maintaining the QS pattern in the intracavitary lead.
- E — Intracavitary and DII leads after the selective block of the anterior internodal tract.
Groups of supraventricular extrasystoles provoked by the mechanical stimulation of the site occupied by the sinoatrial node.

FIGURA 3

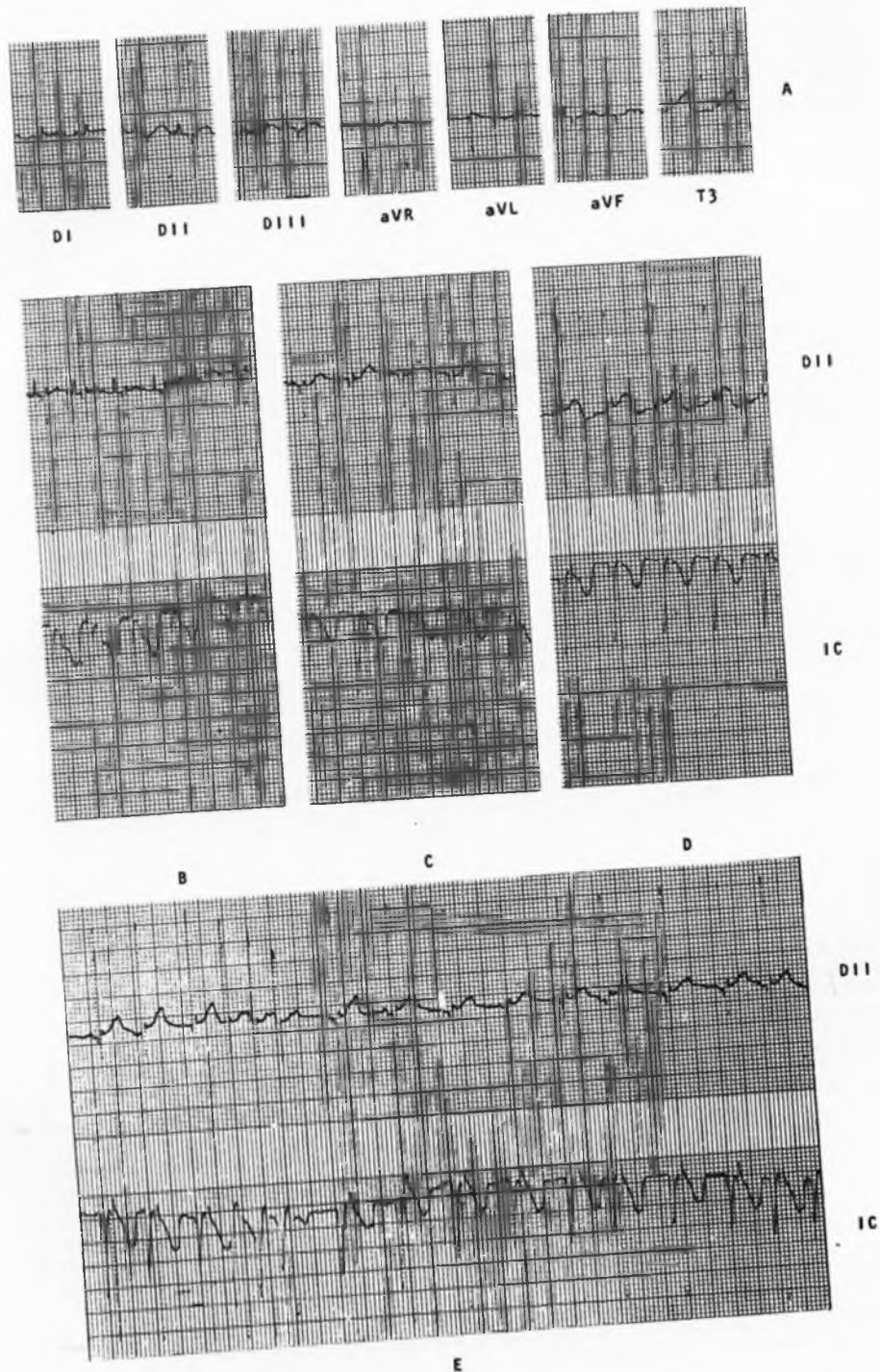


FIGURA 4

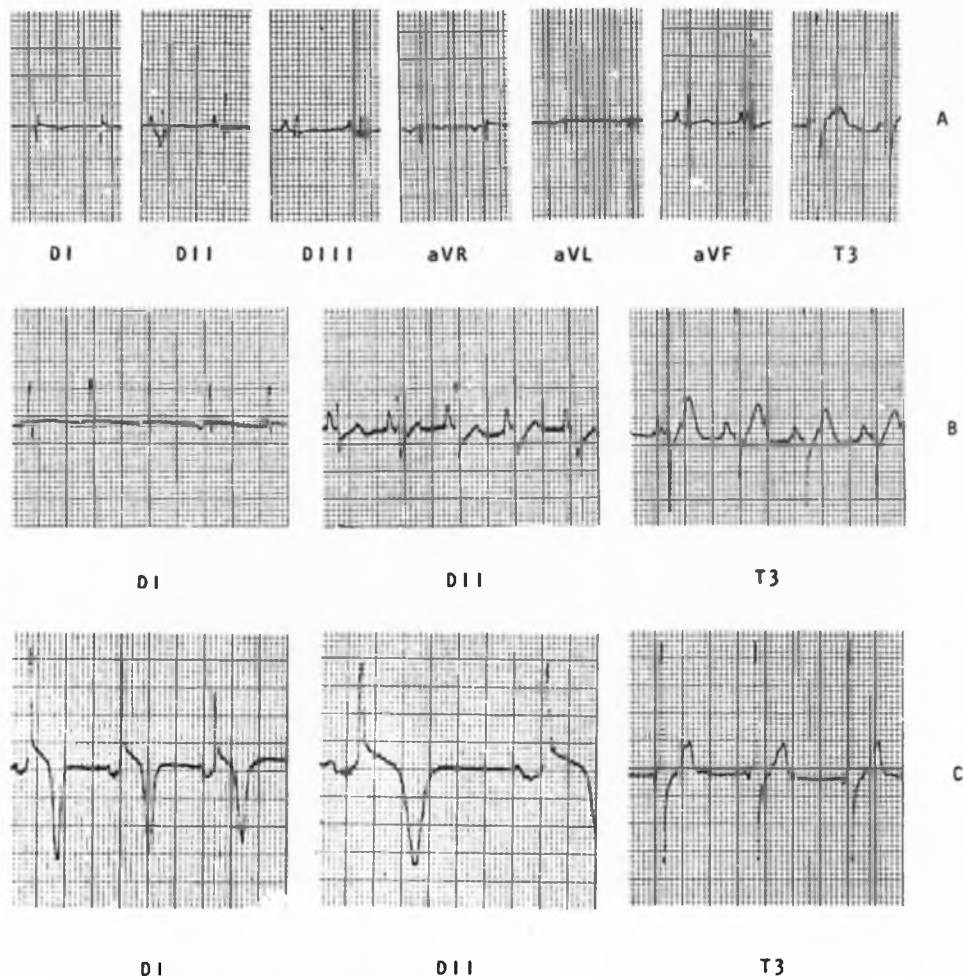
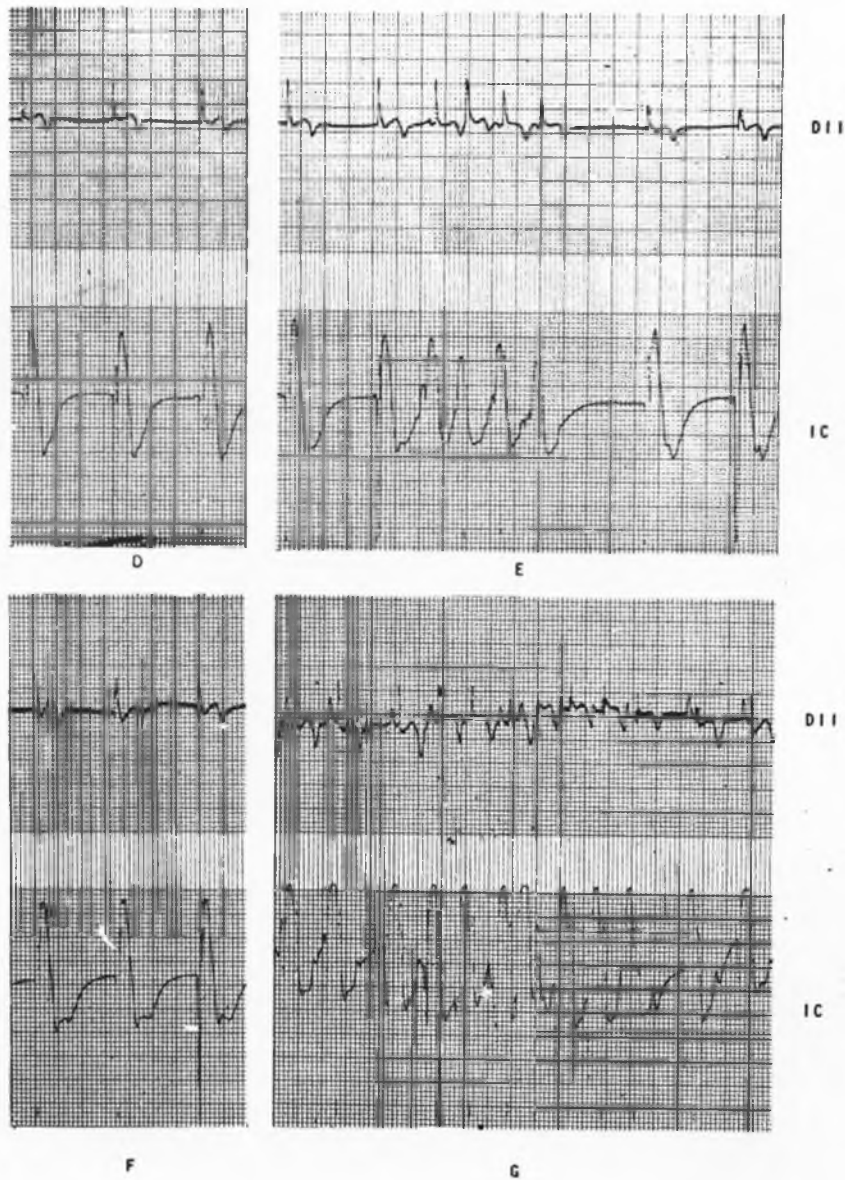


FIGURE 4 — Electrocardiograms showing: SAP deflection to the right while selectively blocking the middle internodal pathway; deflection to the left after successive block of the anterior internodal pathway with shortening of the P-R and conduction by the posterior internodal pathway (James' paranodal tract, forming a "by-pass" between the posterior internodal pathway and the bundle of His); junctional rhythm after final block of the posterior internodal pathway, proving that this tract is used for conduction with short P-R. After blocking the three internodal pathways the mechanical stimulation of the area occupied by the sinoatrial node did not produce positive responses.

- A — Frontal plane leads (DI, DII, DIII, aVR, aVL, aVF and T3) before the selective block of the middle internodal tract.
Isoelectrical P waves in DI (+90°) and positives in T₃ (forward).
- B — DI, DII and T3 leads after selective block of the middle internodal tract.
Negative P waves in DI, positives with a greater magnitude in DII and more positive in T₃, indicating a SAP deflection to the right and forward.
- C — DI, DII and T3 leads after successive block of the anterior internodal pathway.
Isoelectrical P waves in DII, tending to be negative (-45°) and negatives in T₃, indicating a SAP deflection to the left and to the rear. The P-R is short and the morphology of the QRS and the ST-T altered.

FIGURA 4



- D — Simultaneous intracavitary and DII leads after final block of the posterior internodal tract.
 Absence of P waves in DII suggesting junctional rhythm, confirmed by the intracavitary lead, which does not show any atrial activity.
- E — Simultaneous intracavitary and DII leads before blocking the internodal conduction pathways. Groups of supraventricular extrasystoles produced by mechanical stimulation of the area occupied by the sinoatrial node.
- F — Simultaneous intracavitary and DII leads after blocking the three internodal conduction pathways. Junctional rhythm, no response to mechanical stimulation of the site occupied by the sinoatrial node.
- G — Simultaneous intracavitary and DII leads after blocking the three internodal conduction pathways.
 Groups of atrial extrasystoles provoked by mechanical stimulation of the right atrial wall.

FIGURA 5

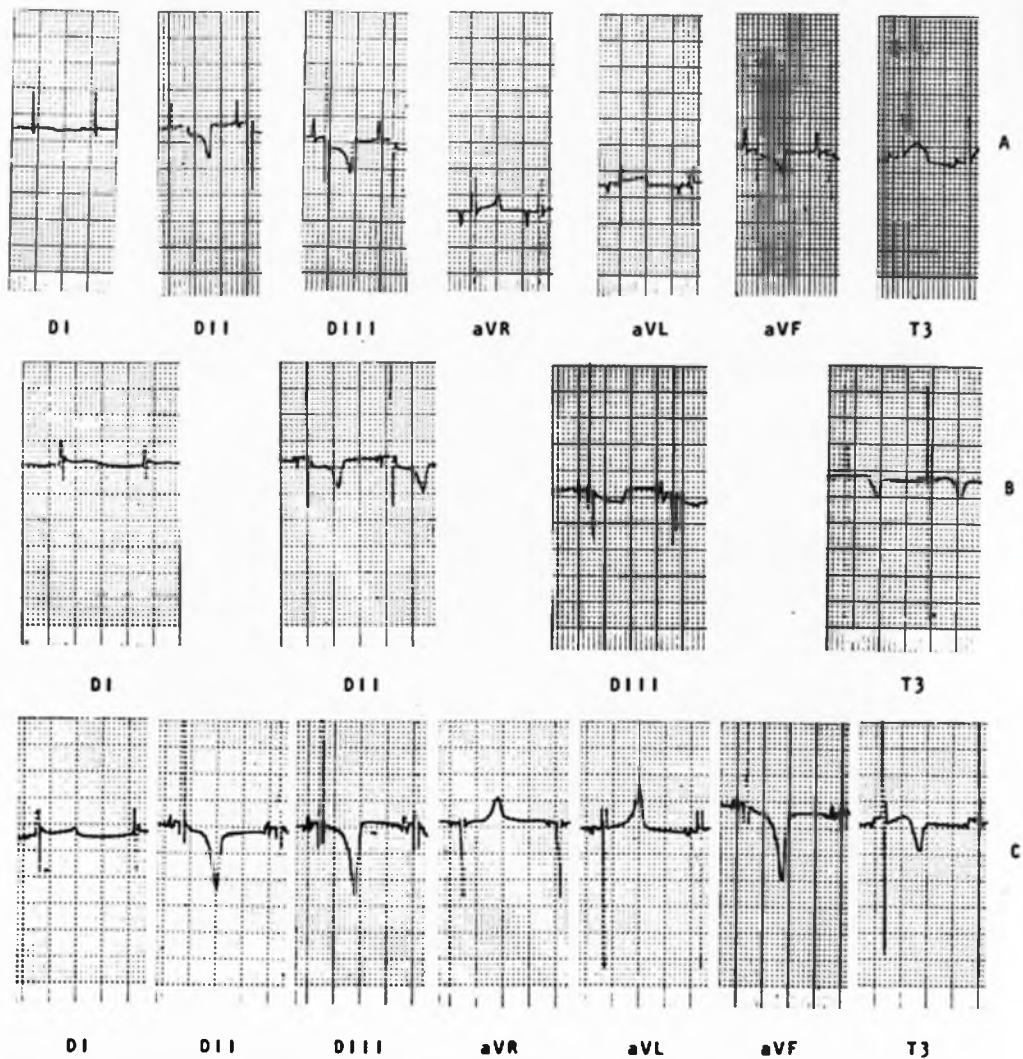


FIGURE 5 — Electrocardiograms showing SAP deflection to the left and to the rear after blocking the anterior internodal pathway; appearance of the junctional rhythm after blocking the three internodal conduction pathways.

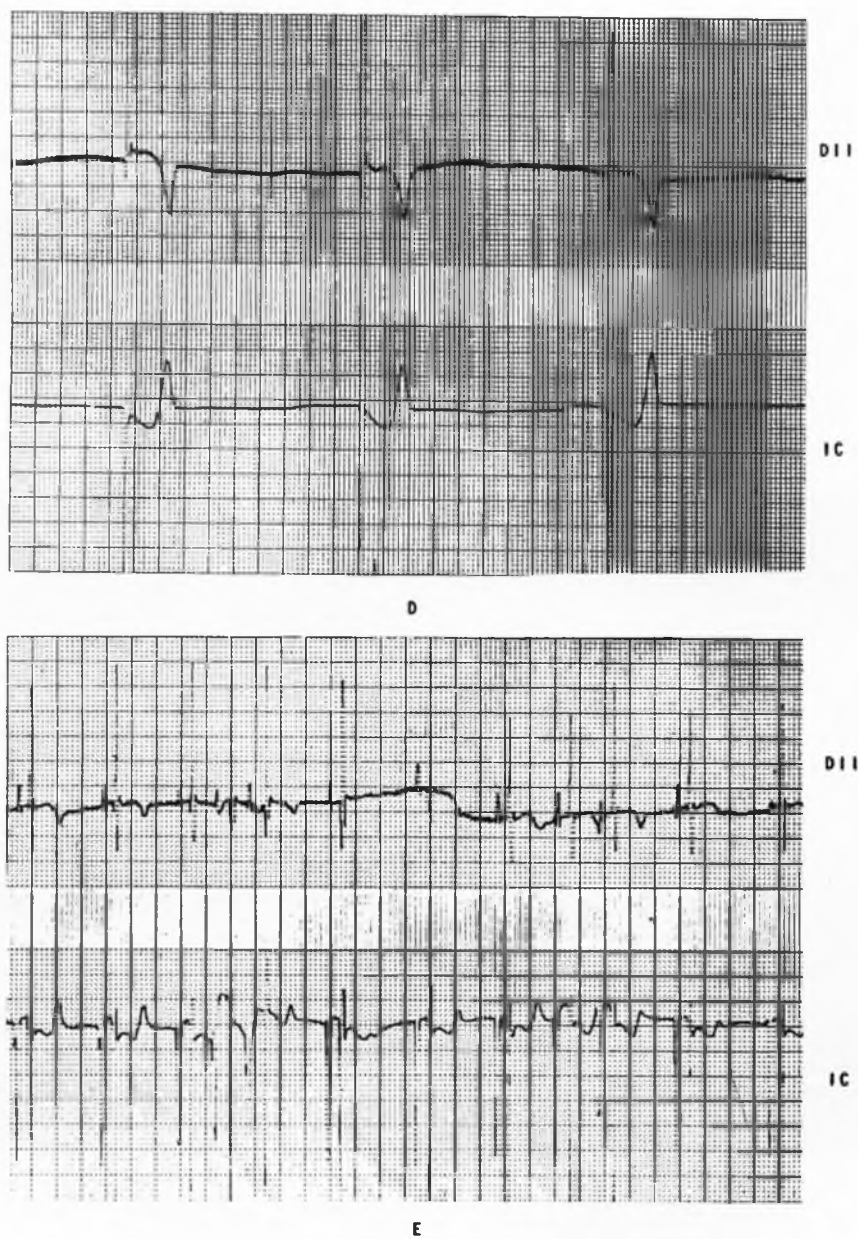
A — Frontal plane leads (DI, DII, DIII, aVR, aVL, aVF) and T3 before the selective block of the anterior internodal pathway.

B — DI, DII, DIII and T3 leads after selective block of the anterior internodal pathway. SAP -30° to the rear.

C — Frontal plane and T3 leads after successive block of the posterior internodal pathway.

No SAP change was noted.

FIGURA 5



- D — Simultaneous DII and intracavitary leads after final block of the middle internodal pathway.
Bradycardiac junctional rhythm with absence of atrial activity clearly shown by the intracavitary lead.
- E — Simultaneous DII and intracavitary leads before blocking the internodal conduction pathways.
Groups of supraventricular extrasystoles provoked by mechanical stimulation of the site occupied by the sinoatrial node.

FIGURE 5 — Electrocardiograms showing SAP deflection to the left and to the rear after blocking the anterior internodal pathway; appearance of the junctional rhythm after blocking the three internodal conduction pathways.

F — DII and intracavitary leads after blocking the three internodal conduction pathways. Slow junctional rhythm, with negative responses to mechanical stimulation of the area occupied by the sinoatrial node.

FIGURA 5

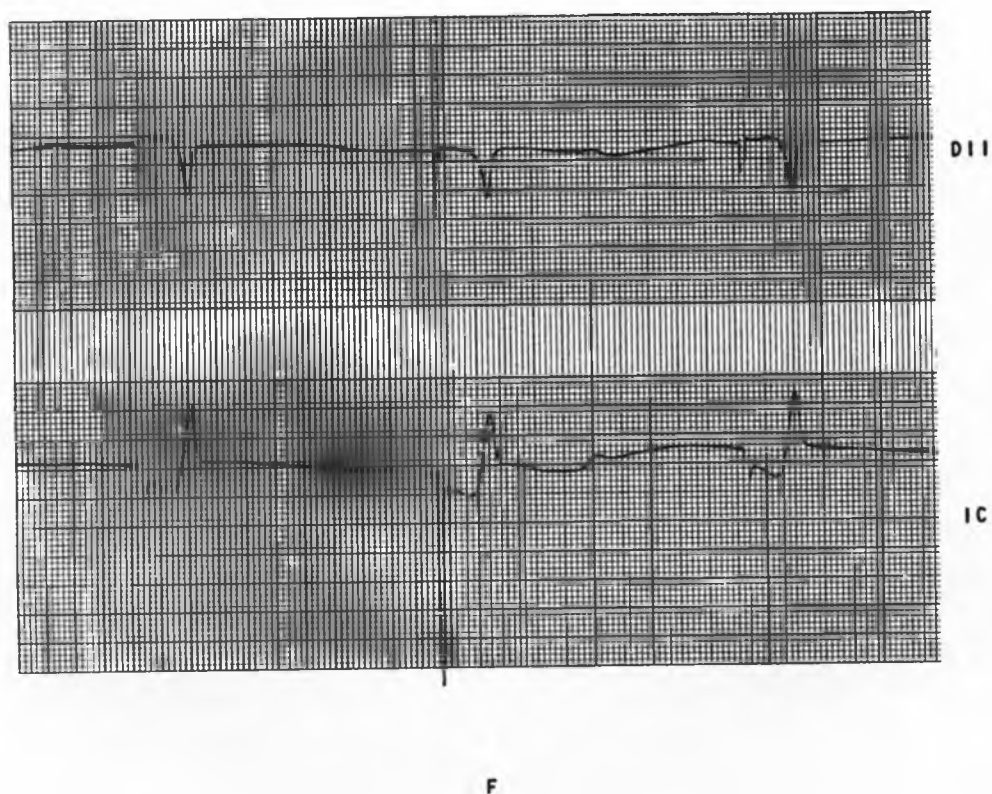


FIGURE 6 — Electrocardiograms where the SAP did not change after the selective block of the middle internodal pathway, and junctional rhythm with blocks of the middle and the anterior pathways, evidencing in this case that there was no conduction of the stimulus by the posterior internodal pathway.

A, B — Intracavitary and DII leads before (A) and after (B) the selective block of the middle internodal pathway.

C — Intracavitary and DII leads after successive block of the anterior internodal pathway. Mean junctional rhythm shown by P waves above the QRS complex in the intracavitary lead.

D — Simultaneous intracavitary and DII leads after blocking the middle and the anterior internodal pathways.

Junctional rhythm with negative responses to mechanical stimulation of the site occupied by the sinoatrial node, evidencing that the posterior internodal pathway was not used for stimuli conduction.

FIGURA 6

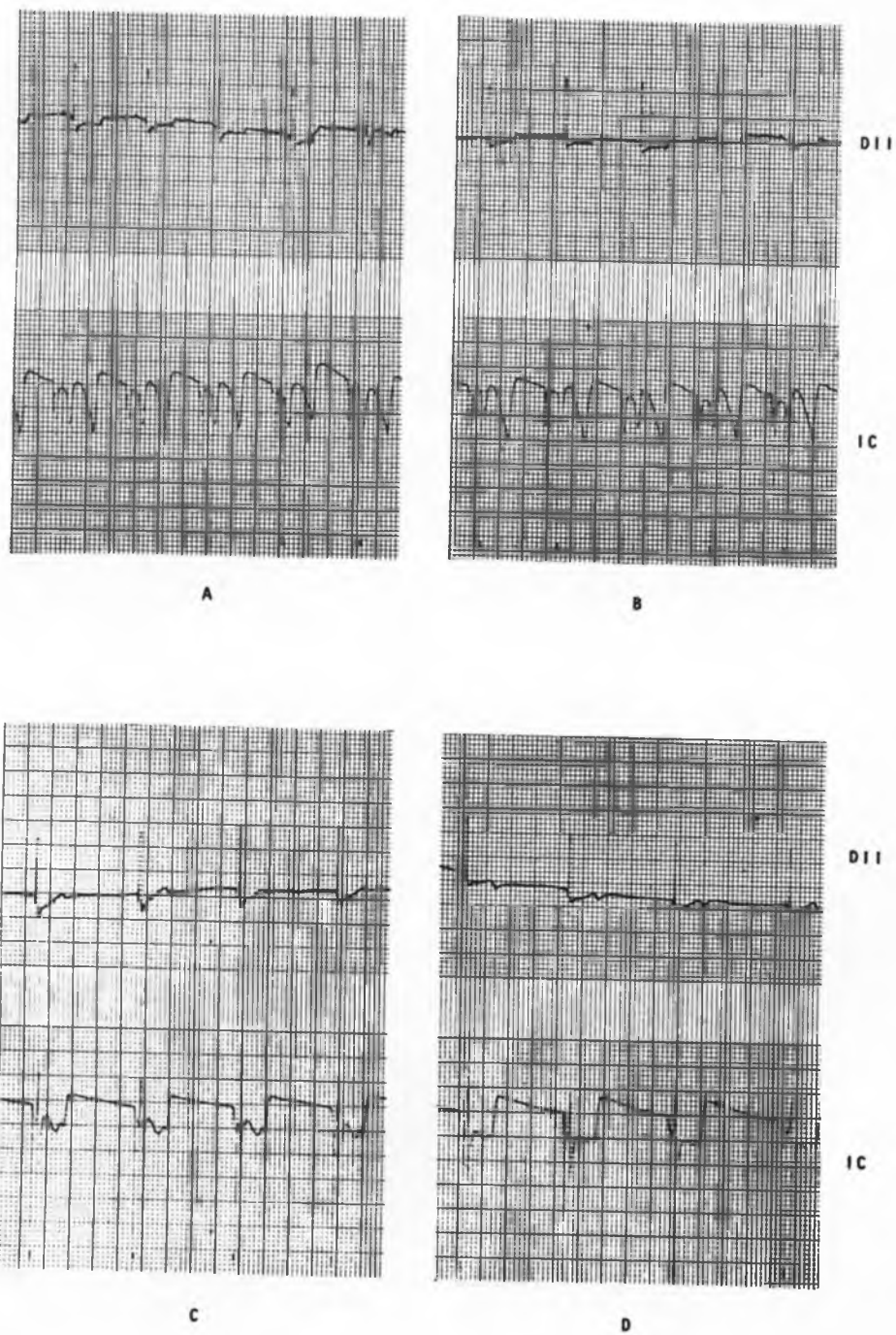


FIGURE 7 — Electrocardiograms with SAE deflection to the left after the selective block of the anterior internodal pathway and shortening of the P-R after successive block of the middle internodal pathway. In this case, the stimulus was conducted by the posterior internodal pathway and probably by the "by-pass" (James' paranodal) tract) to the His bundle.

- A — DII lead before blocking the anterior internodal pathway. Positive P waves ($+80^\circ$).
- B — DII lead after selective block of the anterior internodal pathway. Isoelectrical P waves (-30°).
- C — DII lead after successive block of the middle internodal pathway.
Isoelectrical P waves with short P-R and Positive P waves.
- D — Simultaneous intracavitary and DII leads after blocking the posterior internodal pathway
Bradycardiac junctional rhythm with atrial activation after the QRS complex.

FIGURA 7

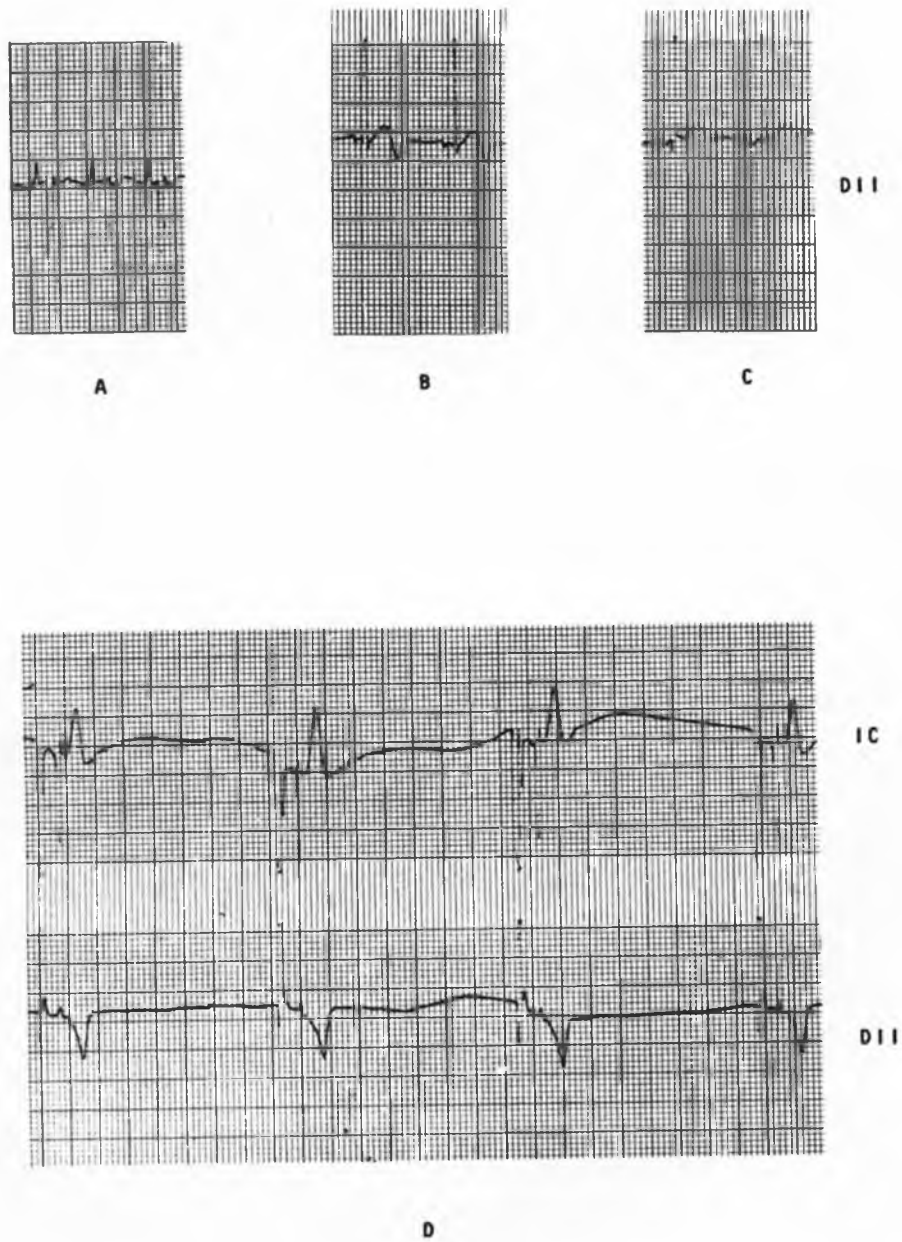


FIGURE 8 — Diagram of the normal mean atrial activation vector and its variations due to selective blocks of the internodal conduction pathways.

- I — Normal atrial activation.

- A — Representative vector of the atrial activation conduction by the middle internodal pathway, directed from top to bottom, from right to left and from the rear to the front.

- M — Representative vector of the atrial activation conduction by the middle internodal pathway, directed from right to left, from the front to the rear and practically parallel to the frontal plane.

- P — Representative vector of the atrial activation conduction by the posterior internodal pathway, directed from right to left, from the front to the rear, also parallel to the frontal plane.

- AP — Resulting atrial activation vector, corresponding to the P wave of the electrocardiogram, situated between $+30^\circ$ to $+90^\circ$ forward.

- II — Atrial activation after blocking the anterior internodal pathway. The AP vector resulting of the M and P components is directed, in relation to the initial AP vector, to the left, upward and backward (-20° to -90°).

- III — Atrial activation after blocking the middle internodal pathway. The AP vector resulting of the A and P components directed from the right to the left, downwards and foreward, showing a small deflection to the right in relation to the initial AP vector.

- IV — Atrial activation after blocking the posterior internodal pathway. The AP vector, resulting of the A and M components is practically superposed on the initial AP vector, due to the insignificant vectorial expression of the posterior internodal tract.

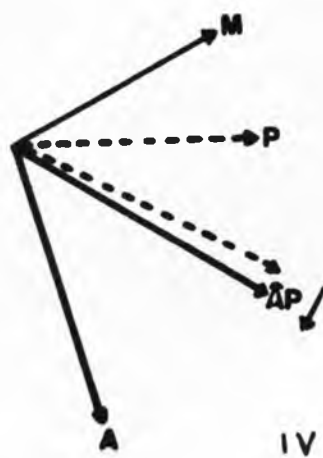
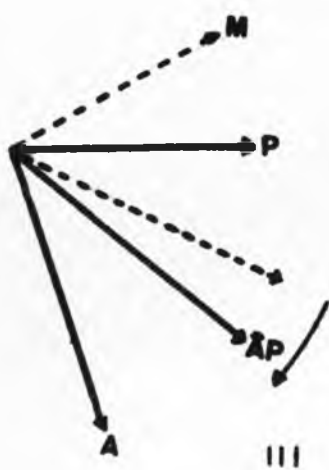
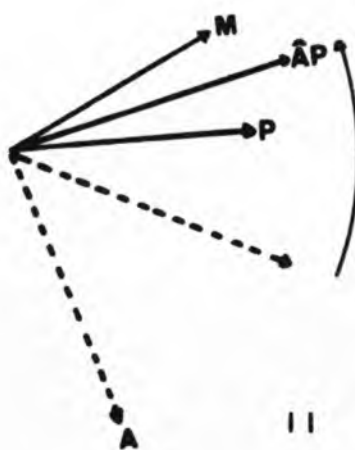
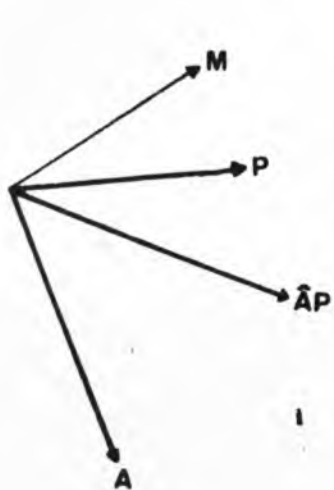


FIGURE 9 — Photography of the (right) *facies atrialis* of a canine heart, showing the suture of the incision performed of nearly the entire extent of the right atrial wall, without jeopardizing the areas through which the internodal conduction pathways course.

SA — area of the sinoatrial node

CR — cranial vena cava

CA — caudal vena cava

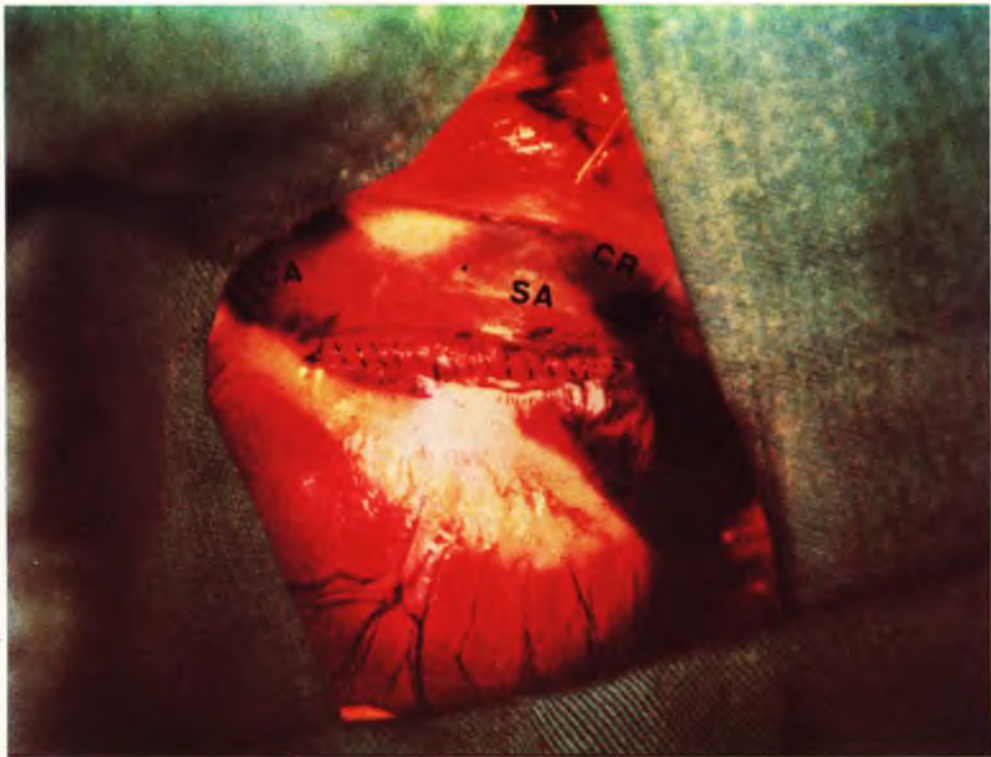

FIGURE 10 — Electrocardiograms showing that atrial myocardial alterations, due to the incision and suture of the right atrial wall without jeopardizing the internodal conduction pathways, do not produce SAP changes which occur by blocking the mentioned pathways.

A — DI, DII, DIII and intracavitary leads before surgery.
Normal P waves, sinusal rhythm.

B — DII and intracavitary leads after incision and suture of the right atrial wall.
Sinusal rhythm with P waves without alteration in relation to the initial ECG (DII).
High unevenness of the Pta (P-R) of 5 mm, corresponding to the atrial lesion (intracavitary lead).

C — DI, DII, DIII leads twenty days after the incision and suture of the right atrial wall.
Sinusal rhythm with P waves without alteration in relation to the initial ECG.
Disappearance of the atrial lesion current (intracavitary lead).

FIGURA 10

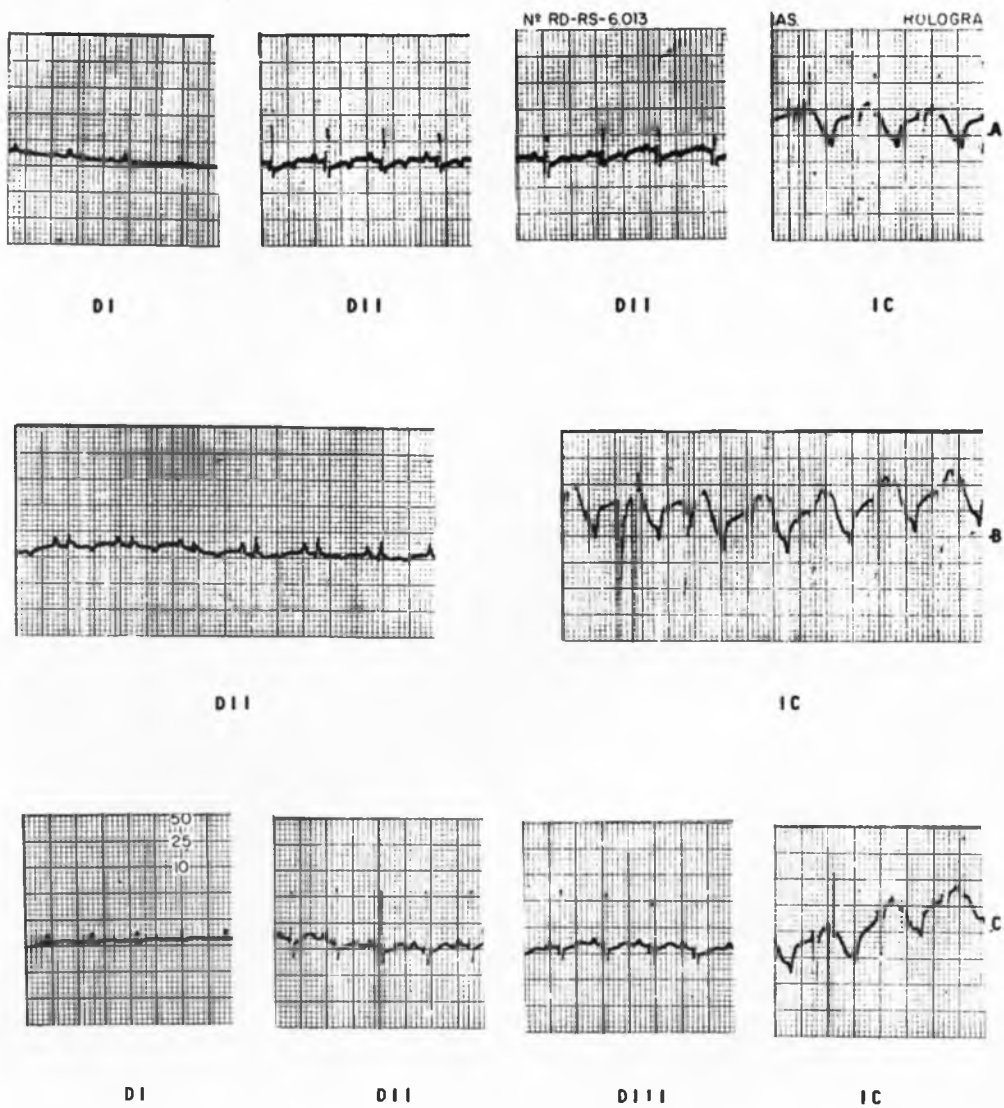


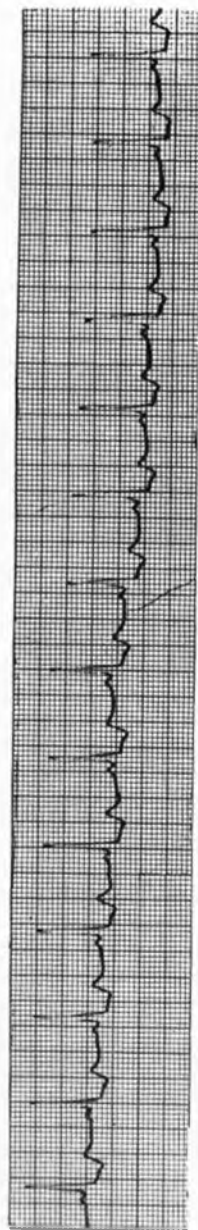
FIGURE 11 — Electrocardiogram performed by the Holter system of a female patient, 81 years, complaining about vertigo.

A — Standard electrocardiogram with positive P waves.

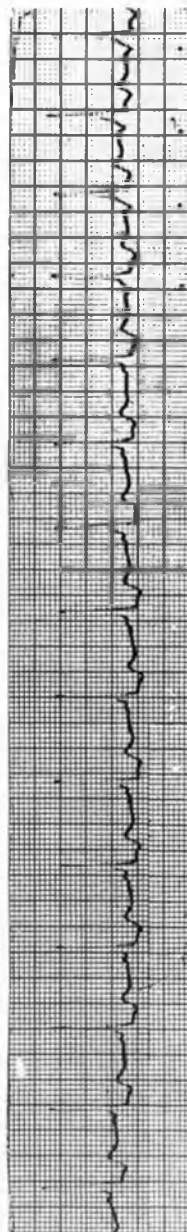B — Electrocardiogram recorded during stroll shows progressive amplitude diminution of the P waves, which become negative, without significant variation of the heart rate; initial thickening of the QRS complexes, very evident in the last four cycles. These findings reveal partial blocks of the internodal conduction pathways, with P wave changes without variation of the heart rate, which suggests a continuance of the sinus rhythm, demonstrated experimentally in this study.

C — Sequent electrocardiogram with P waves returning to initial pattern and concomitant disappearance of the thickening of the QRS complex.

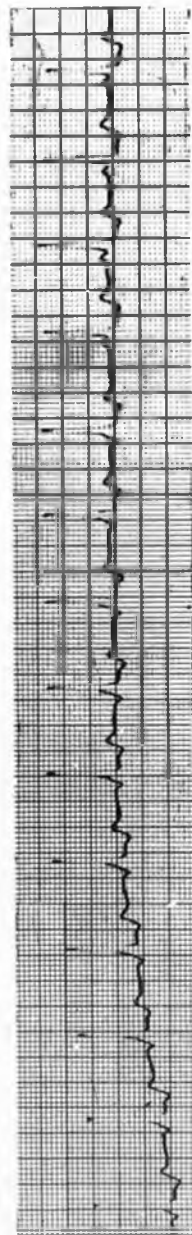
FIGURA 11



A



B



C

FIGURA 12

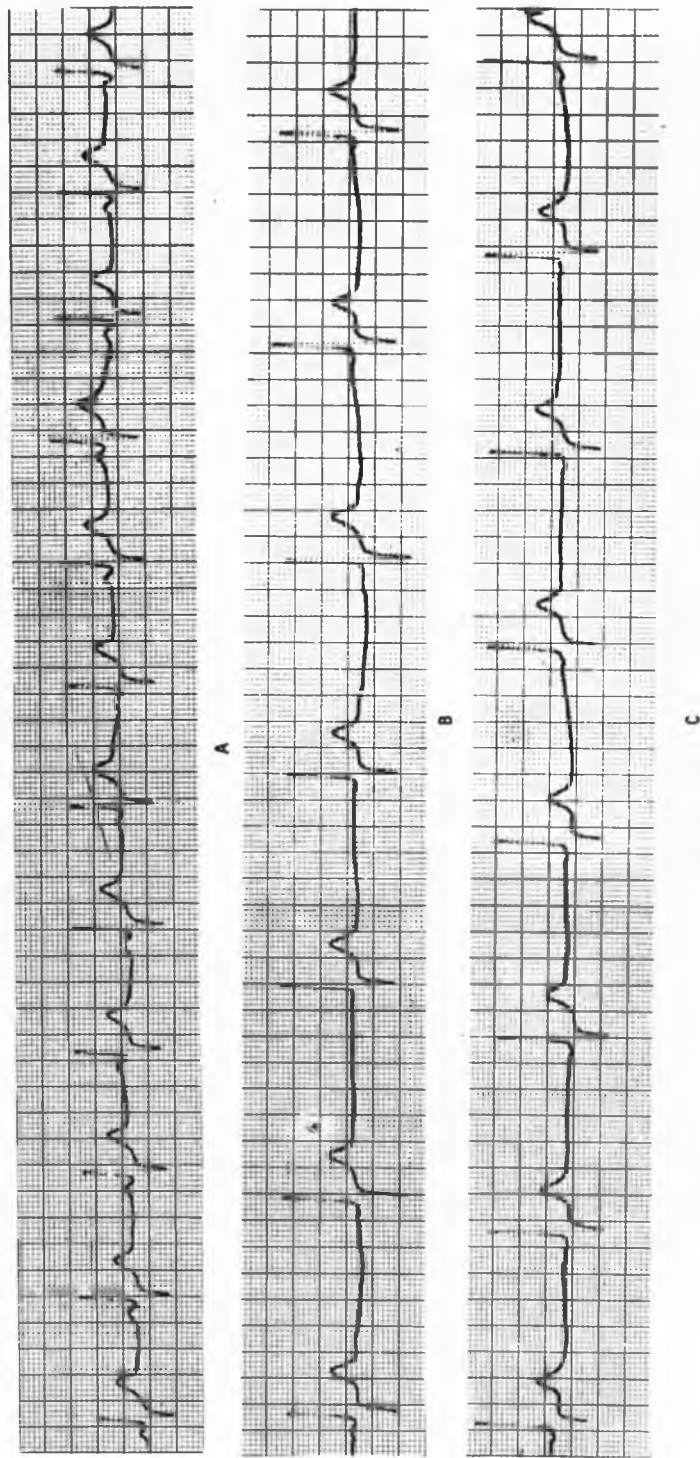
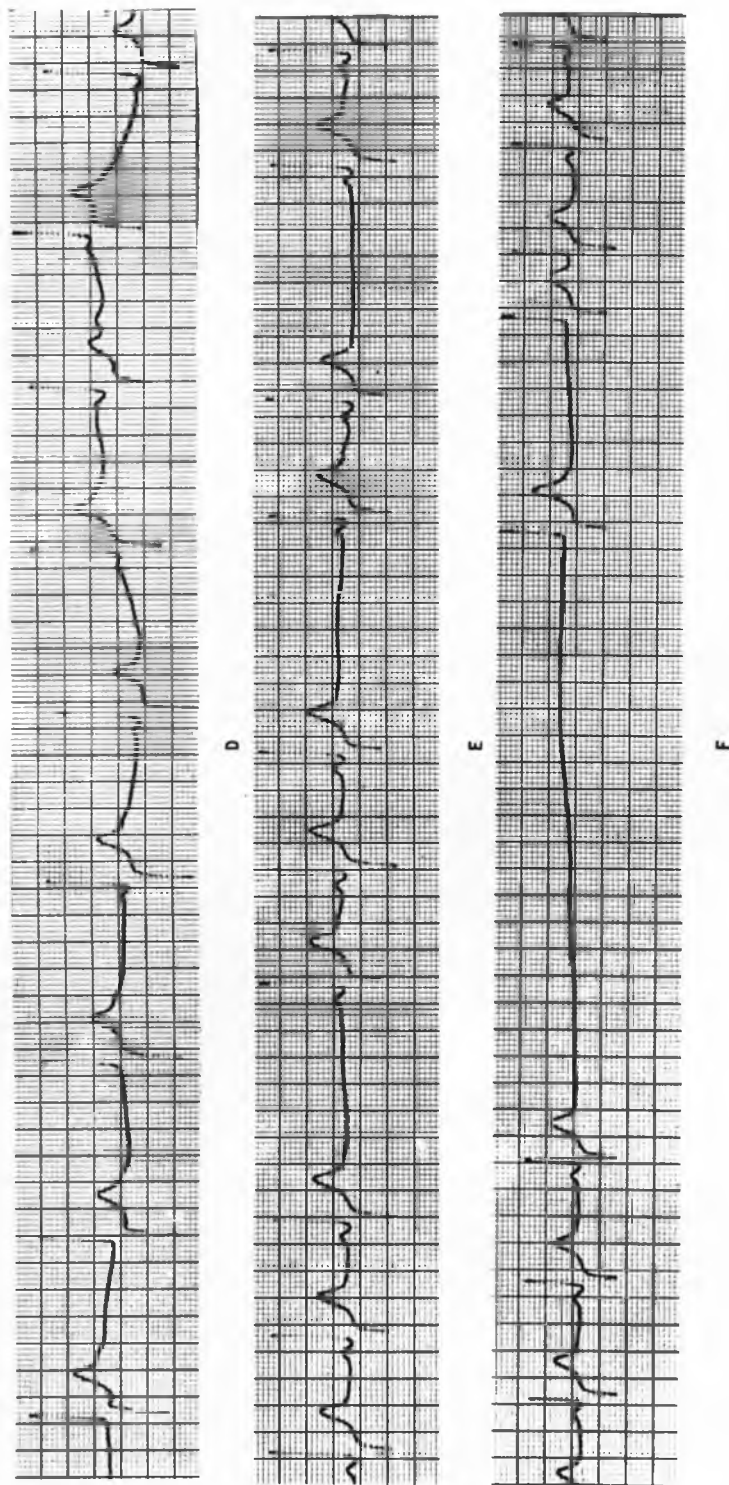


FIGURE 12 — Electrocardiogram performed by the Holter system of a male patient, 67 years, complaining about loss of consciousness.
A — Standard electrocardiogram with positive P waves presenting normal characteristics.
B, C, D — Electrocardiograms of continuous tracing sequences showing morphology variation of the P wave, which changes from positive to isoelectrical or negative, without significant modification of the heart rate, revealing partial blocks of the internodal conduction pathways.

FIGURA 12



- E — Electrocardiogram showing sinus rhythm with sinoatrial block 2:1 periods, marked by double durations cycles in relation to the fundamental cycle, revealing total block of the internodal conduction pathways of intermittent character.
- F — Electrocardiogram showing sinus rhythm, the heart rate being 68 systoles per minute, followed by asystolism periods, interrupted by junctional escapes until the reperussion of the normal rhythm, demonstrating total block of the internodal conduction pathways of lasting character resulting in asystolism.

PEREIRA LEITE, P.; BORELLI, V.; BRITO, F. S. DE; ANDRETTO, R. Bloqueios seletivos experimentais das vias internodais de condução, no cão. *Rev. Fac. Med. vet. Zootec. Univ. S. Paulo*, 13(2):421-58, 1976.

RESUMO: Foram estudados, utilizando o eletrocardiograma convencional, diferentes aspectos da ativação atrial, em 27 cães, distribuídos em quatro diferentes grupos, que tiveram experimentalmente, por ordem, bloqueadas as seguintes vias internodais de condução: anterior, média e posterior; média, anterior e posterior; posterior, anterior e média. Com a interrupção temporária das vias internodais de condução puderam confirmar funcionalmente as vias descritas anatomicamente; verificar a maior importância funcional da via internodal anterior, seguida pelas vias média e posterior; conhecer os desvios apresentados pelo vetor médio representativo da ativação atrial, após bloqueio seletivo de cada uma destas vias e ainda outras importantes modificações eletrocardiográficas decorrentes destas obstruções experimentais. As alterações obtidas, quando comparadas com eletrocardiogramas humanos permitem, também, a melhor interpretação dos distúrbios de condução atrial, encontrados no homem.

UNITERMOS: Bloqueios*; Vias internodais*; Cães.

REFERENCIAS BIBLIOGRAFICAS

- 1 — ANDRETTO, R.; BORELLI, V.; FERNANDES FILHO, A.; SALIBA, A. M.; PEREIRA LEITE, P. Repercussões pulmonares da retirada parcial e total do nó sinu-atrial, no cão. In: CONGRESSO DA SOCIEDADE LUSO-BRASILEIRA DE ANATOMIA, 1, Porto, Portugal, 1973.
- 2 — ANDRETTO, R.; FERNANDES FILHO, A.; BORELLI, V.; SALIBA, A. M.; PEREIRA LEITE, P.; BRITO, F. S.; AKAO, M. H. M. Estudos preliminares sobre a retirada cirúrgica experimental, parcial e total do nó sinu-atrial, no cão. In: CONGRESSO BRASILEIRO DE ANATOMIA, 9, Florianópolis, Brasil, 1972.
- 3 — BACHMANN, G. Inter-auricular time interval. *Amer. J. Physiol.*, Washington, 41: 309, 1916.
- 4 — COPENHAVER, W. M. & TRUEX, R. C. Histology of the atrial portion of the cardiac conduction system in man and other mammals. *Anat. Rec.*, Philadelphia, 114: 601-7, 1952.
- 5 — EYSTER, J. A. E. & MEEK, W. J. Experiments on the origin and conduction of the cardiac impulse. VI. Conduction of the excitation from the sino-auricular node to the right auricle and auriculoventricular node. *Arch. intern. Med.*, Chicago, 18: 775-81, 1916.
- 6 — EYSTER, J. A. E. & MEEK, W. J. Experiments on the origin and propagation of the impulse in the heart. Point of primary negativity in the mammalian heart and the spread of negativity to other regions. *Heart*, London, 5: 119-26, 1914.
- 7 — ERHARDT, L. R. Abnormal atrial activity in lipomatous hypertrophy of the interatrial septum. *Amer. Heart J.*, St. Louis, 87(5): 571-76, 1974.
- 8 — HIS, W. (jr.) Thatigkeit des embryonalen Herzens und deren Bedeutung für die Lehre von der Herzbewegung beim Erwachsenen. In: Curschmann, H. *Arbeiten aus der medicinischen Klinik zu Leipzig*. Leipzig, F. C. W. Vogel, 1893. p. 14.
- 9 — HORIBE, H. Studies on the spread of right atrial activation by means of intracellular microelectrode. *Jap. Circulat. J.*, Nippon, 25: 583-9, 1961.
- 10 — JAMES, T. N. Connecting pathways between the sinus node and A-V node and between the right and the left atrium in the human heart. *Amer. Heart. J.*, St. Louis, 66: 498-506, 1963.
- 11 — JAMES, T. N. & SHERF, L. Specialized tissues and preferential conduction in the atrial of the heart. *Amer. J. Cardiol.*, New York, 28: 414-21, 1971.

- 12 — KEITH, A. & FLACK, M. Form and nature of the muscular connections between the primary divisions of the vertebrate heart. *J. Anat. Physiol.*, London, 41: 172-7, 1907.
- 13 — LEV, M. Conduction system. In: GOULD, S. E. *Pathology of the heart*. 2 ed. Springfield, Charles C. Thomas Publ., 1960, p. 132.
- 14 — LEWIS, T. Galvanometric curves yielded by cardiac beats generated in various areas of the auricular musculature: Pacemaker of the heart. *Heart*, London, 2: 23, 1910.
- 15 — MEEK, W. J. & EYSTER, J. A. E. Experiments on the origin and propagation of the impulse in the heart. III. Effect of vagal stimulation on the location of the pacemaker, the location of the pacemaker in auriculo-ventricular rhythm, and the effect of vagal stimulation on this rhythm. *Heart*, London, 5: 227-36, 1914.
- 16 — MERIDETH, J. & TITUS, J. L. The anatomic atrial connections between the sinus and A-V node. *Circulation*, New York, 37: 566-75, 1968.
- 17 — MOREIRA GOMES, O.; KALLAS, E.; EBAID, M.; VERGINELLI, G.; TSUZUKI, S.; BITTENCOURT, D.; MENGAL, A.; ZERBINI, E. J. Técnica para produção de comunicação interatrial. *Rev. Hosp. Clin. Fac. Med.*, São Paulo, 29: 63-69, 1974.
- 18 — NISHII, N. Experimental studies on the atrial stimulus conduction. I-VI. *Jap. Circulat. J., Nippon*, 22: 137; 348; 635; 675; 751; 845; 1958/59.
- 19 — OOSAWA, M. Histological study on the cardiac conducting system in the atrial portion of the dog's heart. I-V. *Jap. Circulat. J., Nippon*, 23: 548; 718; 1014; 1178; 1183, 1959.
- 20 — PEREIRA LEITE, P. Contribuição ao estudo do diagnóstico eletrocardiográfico do enfarte do miocárdio atrial. São Paulo, 1972. [Tese — Faculdade de Medicina da Universidade Estadual de Campinas].
- 21 — PEREIRA LEITE, P.; BORELLI, V.; SANDOLI DE BRITO, F.; FERNANDES FILHO, A.; MARIANO, M.; ANDRETTO, R. Enfarte atrial experimental no cão. *Arq. bras. Cardiol.*, São Paulo, 125: 169-7, 1972.
- 22 — PURKINJE, J. E. Mikroskopisch-neurologische Beobachtungen. *Arch. Anat. Physiol., Leipzig*, : 281, 1845.
- 23 — ROBB, JANE S.; KAYLOR, C. T.; TUFMAN, W. G. Study of specialized heart tissue at various stages of development of the human fetal heart. *Amer. J. Med.*, New York, 5: 324-31, 1948.
- 24 — SANDOLI DE BRITO, F.; NOGUEIRA DA SILVA, W.; FEDERICO, W. A.; BESEN, D.; NUNES, L. A.; IANHEZ, L. E.; VIEIRA RIOS, M. A. Arritmias de "alto risco", detectadas e estudadas pela eletrocardiografia contínua "Sistema Holter" (DCG) — *Arq. bras. Cardiol.*, São Paulo, 27 (Supl. 1): 88-97, 1974.
- 25 — TAKAYASU, M. & DOSAWA, M. Histological studies on the conducting systems of the atrial portion in dog's heart: I. (Abstr.) *Jap. Circulat. J., Nippon*, 18: 84-89, 1954.
- 26 — TAKAYASU, M. & DOSAWA, M. Studies on the conducting systems between the sinus node and the atrioventricular node. (Abstr.) *Jap. Circulat. J., Nippon*, 18: 84-91, 1954.
- 27 — TATEISHI, Y. Experimental studies on the stimulus conduction of the interatrial septum and its circumferences, particularly the sino-Tawara system: I. Stimulus conduction on the interatrial septum. II. Cutting examination at the interatrial septum and its circumference. *Jap. Circulat. J., Nippon*, 23: 557; 726, 1959.
- 28 — TAWARA, S. *Das Reitzleitungssystem des Säugetierherzens: Eine anatomisch-histologische Studie über das Atrioventricularbündel und die Purkinjeschen Fäden*. Jena, VEB Gustav Fischer Verlag, 1906.
- 29 — THOREL, C. Vorläufige Mitteilung über eine besondere Muskelverbindung zwischen der Cava superior und dem Hisschen Bündel. *Münch. med. Wschr.*, 56: 2159, 1909.
- 30 — THOREL, C. Ueber den Aufbau des Sinus-knotens und seine Verbindung mit der Cava superior und den Wenckbachschen Bündeln. *Münch. med. Wschr.*, 57: 183-92, 1910.

- 31 — TRUEX, R. C. Comparative anatomy and functional considerations of the cardiac conduction system. In: CARVALHO, A. P.; MELLO, W. C. de; HOFFMAN, B. F., ed. the Specialized Tissues of the Heart. Proceedings of the Symposium on the Specialized Tissues of the Heart, Rio de Janeiro, 1960. Amsterdam, Elsevier Publishing Co., 1961, p. 22.
- 32 — WENCKEBACH, K. F. Beiträge zur Kenntnis der menschlichen Herz-tätigkeit. *Arch. Anat. Physiol.*, Leipzig, : 1, 1907.
- 33 — WAGNER, M. I.; LAZZARA, R.; WETSS, R. M.; UDERMAN, B. F. Specialized conducting fibers in the interatrial band. *Circulat. Res.*, 18: 502-11, 1966.
- 34 — YAMADA, K.; HORIBA, M.; SAKAIDA, Y.; OKAJIMA, M.; HORIBE, H.; MURAKI, H.; KOBAYASHI, T. MIYAUCHI, A.; OISHI, H.; NONAGAWA, A.; ISHIKAWA, K.; TOYAMA, J. Origination and transmission of impulse in the right auricle. *Jap. Heart. J.*, Nippon, 6: 71-80, 1965.
- Recebido para publicação em 15-6-76
Aprovado para publicação em 13-9-76