

## CASE REPORT

### FATAL DISSEMINATED CRYPTOCOCCOSIS WITH RENAL INVOLVEMENT IN AN HIV-INFECTED PATIENT

Elizabeth De Francesco DAHER(1,2), Jarinne Camilo Landim NASSERALA(1), Geraldo Bezerra da SILVA JUNIOR(3),  
Adriana Regina Vilarinho de OLIVEIRA(4), José Urbano de MEDEIROS NETO(4) & Anastácio Queiroz SOUSA(2)

#### SUMMARY

**Introduction:** We present a fatal case of disseminated cryptococcosis in a young man whose diagnosis of HIV infection was made at the time of admission to the emergency room. **Case report:** The patient was a twenty-three-year-old man, with a history of daily fever during one month associated with diarrhea, weight loss, headache, vomiting and generalized seizures. He also had a history of diabetes mellitus, alcoholism and drug addiction. Upon physical examination the patient was pale, disoriented and had periods of agitation. White blood cells count was 3,440/mm<sup>3</sup> (5% lymphocytes), hemoglobin was 10g/dL, platelets were 83,000/mm<sup>3</sup>. Creatinine was 0.7 mg/dL; urea 19 mg/dL; Na, K, and liver enzymes were within normal limits. Lactic dehydrogenase was 494 IU/L. Cerebrospinal fluid (CSF) analysis revealed 10 white blood cells/mm<sup>3</sup> (58% neutrophils, 31% lymphocytes, 11% monocytes) and 2 red blood cells/mm<sup>3</sup>. India ink test revealed six *Cryptococcus* yeasts/mm<sup>3</sup>. CSF glucose was 122 mg/dL and protein was 36 mg/dL. VDRL test was negative and anti-HIV test was positive. Intravenous hydration, insulin, phenytoin, fluconazole, pyrimethamine, sulfadiazine, folic acid, and amphotericin B were started. The patient did not improve and became obtunded and hypotensive. He was intubated and put on mechanical respiration. He received vasoactive drugs and died less than 24 hours after admission. A post-mortem examination was performed and revealed disseminated cryptococcosis, with severe involvement of the kidneys. **Conclusion:** Cryptococcosis, as a rule, is a systemic disease that affects mostly immunocompromised individuals, especially patients with AIDS. When diagnosed late in its course it has a very high mortality.

**KEYWORDS:** *Cryptococcus* sp.; HIV; AIDS; Renal diseases; Acute kidney injury.

#### INTRODUCTION

Cryptococcosis as a rule is a systemic mycosis, more frequently seen in patients with AIDS. It is the third most frequent opportunistic disease of the central nervous system (CNS) in this population. It can also be found in other conditions, such as patients with neoplasms, and can present a benign course<sup>3</sup>. The disease is rare in immunocompetent individuals, but there are reports of cases<sup>6</sup>. Its prevalence ranges from 2.9 to 13.3% in most countries, however it reaches 30% in Africa as well as in Southeast Asia countries. It represents an important cause of mortality in AIDS patients even with specific treatment.

It is estimated that there are 957,900 cases of cryptococcosis worldwide per year<sup>11</sup>. Most cases are diagnosed as insidious meningoencephalitis with fever. Others (50% of the cases) present fever, headache, vomiting and altered mental status. Lack of specificity of clinical manifestations delays the diagnosis and worsens the prognosis<sup>11</sup>.

We present a fatal case of disseminated cryptococcosis in a young man whose diagnosis of HIV infection was made at the time of admission to the emergency room.

#### CASE REPORT

A twenty-three-year-old man was admitted to the emergency room of an infectious disease hospital in Northeast Brazil with a one-month history of daily fever associated to diarrhea with mucus and weight loss of fifteen kilograms in six months. One week prior to admission, the patient's clinical picture worsened with headache, vomiting, disorientation and generalized tonic-clonic seizures. The patient also had a history of diabetes mellitus, tobacco smoking, alcoholism and drug addiction. He had no prior history of hospitalization. Upon physical examination the patient was pale, disoriented, and had periods of agitation. He had rhonchi on the pulmonary auscultation. Abdomen was tender on palpation of the upper right quadrant, liver and spleen were not palpable and no

(1) Division of Nephrology, *Hospital Universitário Walter Cantídio*, Federal University of Ceara, Fortaleza, CE, Brazil.

(2) Department of Internal Medicine, Post-Graduation Program in Medical Sciences, Faculty of Medicine, Federal University of Ceara, Fortaleza, CE, Brazil.

(3) School of Medicine, Master in Collective Health, University of Fortaleza, Fortaleza, CE, Brazil.

(4) Department of Pathology, Faculty of Medicine, Federal University of Ceara, Fortaleza, CE, Brazil.

**Correspondence to:** Elizabeth De Francesco Daher, R. Vicente Linhares 1198, 60135-270 Fortaleza, CE, Brazil. E-mail [ef.daher@uol.com.br](mailto:ef.daher@uol.com.br), [geraldobezerrajr@yahoo.com.br](mailto:geraldobezerrajr@yahoo.com.br)

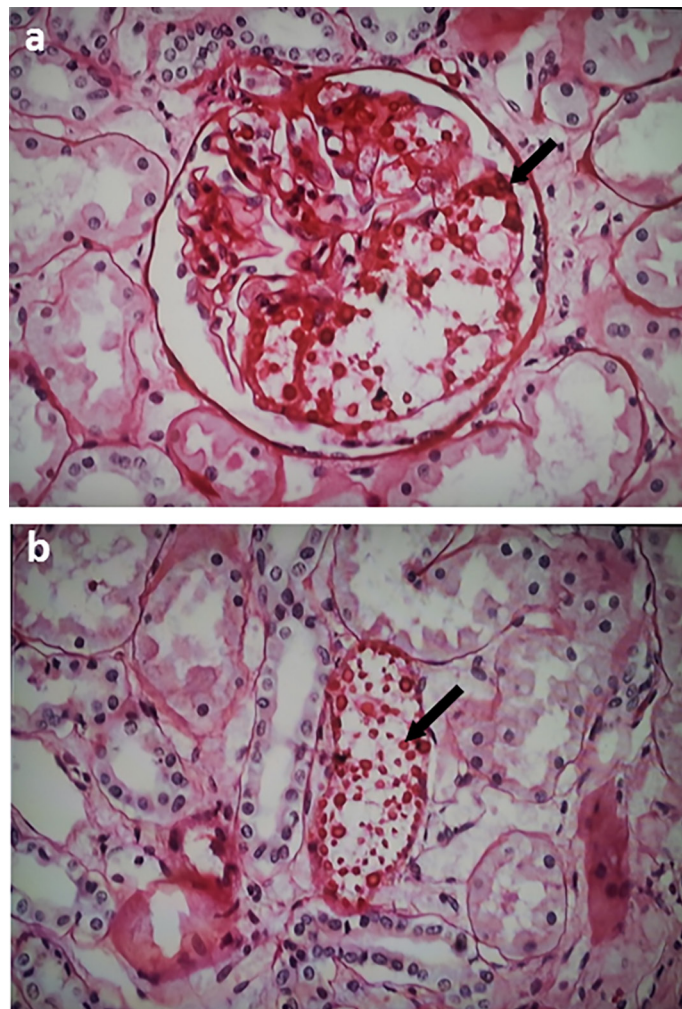
edema was seen in the lower extremities. Nuchal rigidity and meningeal irritation signs were present, however motor deficit was not identified.

Laboratory tests upon admission showed hemoglobin 10 g/dL, 3,440 leukocytes/mm<sup>3</sup>, (4% bands, 45% neutrophils, 5% lymphocytes), 83,000 platelets/mm<sup>3</sup>, urea was 19 mg/dL, creatinine 0.7 mg/dL, ionic calcium 1.23 mEq/L, sodium 130 mEq/L, potassium 4.2 mEq/L, and liver enzymes (ALT and AST) were within normal limits; lactic dehydrogenase was 494 IU/L. Cerebrospinal fluid (CSF) analysis revealed 10 white blood cells/mm<sup>3</sup> (58% neutrophils, 31% lymphocytes, 11% monocytes) and 2 red blood cells/mm<sup>3</sup>. CSF glucose was 122 mg/dL and protein 36 mg/dL. India ink test revealed six *Cryptococcus* yeasts/mm<sup>3</sup>. VDRL test was negative and anti-HIV test positive. CD4 count was 40/mm<sup>3</sup>. Blood glucose was 344 mg/dL. Intravenous hydration, insulin, phenytoin, fluconazole, pyrimethamine, sulfadiazine, folic acid, and amphotericin B were started. The patient did not improve and became obtunded and hypotensive. He was then intubated and put on mechanical ventilation. Arterial blood gases after intubation: pH 7.52, PaCO<sub>2</sub> 28.9 mmHg, HCO<sub>3</sub> 26.6 mmEq/L, PaO<sub>2</sub> 77.9 mmHg, SaO<sub>2</sub> 96.6% and FiO<sub>2</sub> 70%. Vasoactive drugs were added and the patient died less than 24 hours after admission. A post-mortem examination was performed and revealed disseminated cryptococcosis. The histopathology of the kidneys revealed severe renal involvement with *Cryptococcus* sp. in the glomerulus and interstitium (Fig. 1).

## DISCUSSION

We presented a fatal case of cryptococcosis, in which the patient only sought medical attention a month after symptoms' onset. In a prospective study in Brazil, from 1998 to 2003, 96 cases of cryptococcosis were diagnosed microbiologically and 78 (81.25%) had AIDS<sup>4</sup>. Cryptococcosis was diagnosed by direct microscopy in 98.3% of cases, however the culture revealed *Cryptococcus* in 100%. The latex agglutination test is considered a very sensitive and specific technique in the detection of this fungus in CSF. It can be used to monitor treatment as well as in diagnosing relapses after an seemingly successful therapy. In a Brazilian study, despite appropriate treatment, 70 patients died (72.9%); 60 (62.5%) of these deaths occurred in AIDS patients, demonstrating that this systemic mycosis is accompanied by a very high mortality<sup>4</sup>. In another cohort of patients with cryptococcosis, in Thailand, favorable clinical response was observed in 55.2% of cases, and the six month survival rate was 67.2%<sup>2</sup>. Even in immunocompetent individuals, mortality due to cryptococcal infection can be as high as 51%<sup>8</sup>. Our patient had diabetes mellitus, which seems to be a risk factor for developing disseminated cryptococcosis due to defects in the host defense mechanisms associated with hyperglycemia<sup>9</sup>. A recent study highlighted possible mechanisms to explain the pathophysiology of HIV-associated cryptococcosis. It was demonstrated that high levels of fungal uptake by macrophages *in vitro*, but not the intracellular proliferation rate, were associated with cerebrospinal fluid fungal burden and long-term patient survival. High-uptake strains were hypocapsular and exhibited enhanced laccase activity. Fungal isolates with greater laccase activity exhibited heightened survival *ex vivo* in purified CSF and resistance to clearance following the patient antifungal treatment<sup>12</sup>.

There is little data published on kidney involvement in cryptococcosis. This case report illustrates the presence of *Cryptococcus* in the glomerulus, interstitium and renal tubules. As the disease had a rapid and fatal course,



**Fig. 1** - Main renal findings. (a) Renal biopsy showing numerous encapsulated yeast forms (*Cryptococcus* sp.) in glomerulus, interstitium and in (b) renal tubule (black arrow). PAS 400x.

there was no specific clinical or laboratory manifestation of kidney involvement, only the unquestionable presence of *Cryptococcus* in kidney histopathology. Kidney involvement in cryptococcosis is rarely described. The fungus has already been isolated in the urine of HIV-infected patients, evidencing its tropism to the kidneys<sup>7</sup>. In a recent study of 49 patients with cryptococcosis and without HIV, acute kidney injury was seen in 47% of cases<sup>8</sup>. BOLLÉE *et al.*<sup>1</sup> reported the case of an HIV-infected patient with acute kidney injury due to disseminated cryptococcosis, which was successfully treated with plasma exchange therapy. This patient has also developed nephrotic range proteinuria, which evidenced glomerular involvement in cryptococcosis<sup>1</sup>. RAMDIAL *et al.*<sup>10</sup> described the cases of two HIV-infected children with cryptococcosis complicated by renal involvement. Renal biopsy showed cryptococcal-associated immune reconstitution inflammatory syndrome in one of these patients based on the clinicopathological profile and the presence of segmental glomerular and an interstitial lymphoplasmacytic and granulomatous reaction to *Cryptococcus neoformans*, with predominance of capsule-deficient fungal forms. The other patient presented typical HIV-associated nephropathy with focal intra-tubular and interstitial *C. neoformans* yeasts

in renal biopsy<sup>10</sup>. The exact pathophysiology of kidney involvement in cryptococcosis remains unclear.

Recommendations for specific treatment of cryptococcal meningoencephalitis can be found in the Brazilian cryptococcosis guidelines<sup>5</sup>. According to the guidelines, treatment should initiate with 0.7 to 1.0 mg/kg/day of amphotericin B (maximum 50 mg), associated with 5-flucytosine in a dose of 100 mg/kg/day, given for two weeks as induction treatment. After this period, oral fluconazole 400 mg/day is indicated, for 10 weeks, as a maintenance therapy<sup>5</sup>. It is possible that the use of other antifungal agents, such as voriconazole or posaconazole, could change this fatal outcome, particularly in immunosuppressed patients, as *in vitro* studies have demonstrated an excellent effect of these drugs on this fungus<sup>11</sup>.

In the present case, the disease severity and the fast evolution to death in less than 24 hours after hospital admission did not allow appropriate treatment, started with fluconazole.

In conclusion, cryptococcosis is a systemic mycosis that affects immunocompromised patients, with a high frequency among HIV-infected individuals, mainly those who develop AIDS. It presents as a severe disease with high mortality, especially when the diagnosis is delayed.

## DISCLOSURE

EFD received a grant from the *Conselho Nacional de Desenvolvimento Científico e Tecnológico, CNPq* (Brazilian Research Council). The funders had no role in study design, data collection and analysis, decision to publish or preparation of the manuscript.

## RESUMO

### Criptococose disseminada fatal com envolvimento renal em paciente infectado pelo HIV

**Introdução:** Apresentamos um caso fatal de criptococose disseminada em homem jovem cujo diagnóstico de HIV foi feito no momento da admissão na emergência. **Relato de caso:** O paciente, de 23 anos, sexo masculino, tinha história de febre diária de um mês de duração, associada à diarreia, perda de peso, cefaleia, vômitos e convulsões generalizadas. Tinha ainda história de diabetes mellitus, alcoolismo e drogadição. Ao exame físico havia palidez, desorientação e períodos de agitação. Os exames laboratoriais mostraram 3.440 leucócitos/mm<sup>3</sup> (5% linfócitos), hemoglobina de 10 g/dL, 83.000 plaquetas/mm<sup>3</sup>, creatinina de 0,7mg/dL, ureia de 19 mg/dL, Na, K e enzimas hepáticas dentro dos limites da normalidade. A lactato desidrogenase era 494 UI/L. Análise do líquido revelou 10 leucócitos/mm<sup>3</sup> (58% neutrófilos, 31% linfócitos, 11% monócitos) e 2 hemácias/mm<sup>3</sup>, glicose de 122 mg/dL e proteína de 36 mg/dL. A análise com tinta da Índia revelou seis blastoconídios de *Cryptococcus*/mm<sup>3</sup>. O VDRL foi negativo e o anti-HIV positivo.

Foi iniciado tratamento com hidratação venosa, insulina, fenitoína, fluconazol, pirimetamina, sulfadiazina, ácido fólico e anfotericina B. O paciente não apresentou melhora e evoluiu com obnubilação e hipotensão, sendo intubado e iniciada ventilação mecânica. Foram administradas drogas vasoativas, e o paciente evoluiu a óbito menos de 24h após a admissão. A autópsia revelou criptococose disseminada, com grave envolvimento renal. **Conclusão:** A criptococose é via-de-regra, doença sistêmica que afeta principalmente indivíduos imunocomprometidos, especialmente com AIDS, e quando diagnosticada tardiamente apresenta alta mortalidade.

## REFERENCES

1. Bollée G, Touzot M, Mechai F, Royal V, Lefrère F, Bougnoux ME, *et al.* Plasma exchange for disseminated cryptococcosis. *Am J Kidney Dis.* 2009;53:673-6.
2. Chayakulkeeree M, Wangchinda P. Clinical characteristics and outcomes of patients with cryptococcal meningoencephalitis in a resource-limited setting. *J Med Assoc Thai.* 2014;97(Suppl 3):S26-34.
3. Martin-Blondel G, Ysebaert L. Images in clinical medicine. Disseminated cryptococcosis. *N Engl J Med.* 2014;370:1741.
4. Moreira TA, Ferreira MS, Ribas RM, Borges AS. Criptococose: estudo clínico-epidemiológico, laboratorial e das variedades do fungo em 96 pacientes. *Rev Soc Bras Med Trop.* 2006;39:255-8.
5. Moretti ML, Resende MR, Lazéra MS, Colombo AL, Shikanai-Yasuda MA. Consenso em criptococose - 2008. *Rev Soc Bras Med Trop.* 2008;41:524-44.
6. Panigrahi MK, Kumar NN, Jaganathan V, Kumar SV. Pulmonary cryptococcosis with cryptococcal meningitis in an immunocompetent host. *Lung India.* 2014;31:152-4.
7. Poloni JA, Rotta LN, Voegeli CF, Pasqualatto AC. Cryptococcus within a urinary cast. *Kidney Int.* 2013;84:218.
8. Pongmekin P, Chongtrakool P, Santanirand P, Kiertiburanakul S. Clinical characteristics and mortality risk factors of cryptococcal infection among HIV-negative patients. *J Med Assoc Thai.* 2014;97:36-43.
9. Poojary S, Khatu S. Disseminated cryptococcosis in a diabetic patient. *Cutis.* 2014;94:91-5.
10. Ramdial PK, Sing Y, Deonarain J, Bhimma R, Chotey N, Sewram V. Pediatric renal cryptococcosis: novel manifestations in the acquired immunodeficiency syndrome era. *Int J Surg Pathol.* 2011;19:386-92.
11. Rothe C, Sloan DJ, Goodson P, Chikafa J, Mukaka M, Denis B, *et al.* A prospective longitudinal study of the clinical outcomes from cryptococcal meningitis following treatment induction with 800 mg oral fluconazole in Blantyre, Malawi. *PLOS ONE.* 2013;8:e67311.
12. Sabiiti W, Robertson E, Beale MA, Johnston SA, Brouwer AE, Loyse A, *et al.* Efficient phagocytosis and laccase activity affect the outcome of HIV-associated cryptococcosis. *J Clin Invest.* 2014;124:2000-8.

Received: 15 October 2014

Accepted: 10 November 2014