

Septic shock, hyperferritinemic syndrome, and multiple organ dysfunction without respiratory failure in a patient with disseminated histoplasmosis and advanced HIV disease

Jussemara Souza da Silva ¹, Bruno Correia Ernandes ¹, Carol Lee Luna Fernandes¹, Ademir Silva Correia ², Cesar Cilento Ponce ^{3,4}, Jaques Sztajnbok ⁵, Camila Rodrigues ^{1,6}, José Ernesto Vidal ^{6,7,8}

¹Instituto de Infectologia Emílio Ribas, Departamento de Infectologia, São Paulo, São Paulo, Brazil

²Instituto de Infectologia Emílio Ribas, Divisão de Apoio ao Diagnóstico e Terapêutica, Seção de Radiologia, São Paulo, São Paulo, Brazil

³Instituto de Infectologia Emílio Ribas, Departamento de Patologia, São Paulo, São Paulo, Brazil

⁴Instituto Adolfo Lutz, Núcleo de Patologia, São Paulo, São Paulo, Brazil

⁵Instituto de Infectologia Emílio Ribas, Unidade de Terapia Intensiva, São Paulo, São Paulo, Brazil

⁶Universidade de São Paulo, Faculdade de Medicina, Departamento de Moléstias Infecciosas e Parasitárias, São Paulo, São Paulo, Brazil

⁷Instituto de Infectologia Emílio Ribas, Departamento de Neurologia, São Paulo, São Paulo, Brazil

⁸Universidade de São Paulo, Faculdade de Medicina, Hospital das Clínicas, Laboratório de Investigação Médica (LIM-49), São Paulo, São Paulo, Brazil

Correspondence to: José Ernesto Vidal
Universidade de São Paulo, Faculdade de Medicina, Hospital das Clínicas, Laboratório de Investigação Médica (LIM-49), Av. Dr. Enéas Carvalho de Aguiar, 470, CEP 05403-000, São Paulo, SP, Brazil
Tel: + 55 11 3061-7017

E-mail: josevibe@gmail.com

Received: 16 November 2022

Accepted: 27 January 2023

ABSTRACT

AIDS-related disseminated histoplasmosis (DH) can cause septic shock and multiorgan dysfunction with mortality rates of up to 80%. A 41-year-old male presented with fever, fatigue, weight loss, disseminated skin lesions, low urine output, and mental confusion. Three weeks before admission, the patient was diagnosed with HIV infection, but antiretroviral therapy (ART) was not initiated. On day 1 of admission, sepsis with multiorgan dysfunction (acute renal failure, metabolic acidosis, hepatic failure, and coagulopathy) was identified. A chest computed tomography showed unspecific findings. Yeasts suggestive of *Histoplasma spp.* were observed in a routine peripheral blood smear. On day 2, the patient was transferred to the ICU, where his clinical condition progressed with reduced level of consciousness, hyperferritinemia, and refractory septic shock, requiring high doses of vasopressors, corticosteroids, mechanical ventilation, and hemodialysis. Amphotericin B deoxycholate was initiated. On day 3, yeasts suggestive of *Histoplasma spp.* were observed in the bone marrow. On day 10, ART was initiated. On day 28, samples of peripheral blood and bone marrow cultures revealed *Histoplasma spp.* The patient stayed in the ICU for 32 days, completing three weeks of intravenous antifungal therapy. After progressive clinical and laboratory improvement, the patient was discharged from the hospital on oral itraconazole, trimethoprim-sulfamethoxazole, and ART. This case highlights the inclusion of DH in the differential diagnosis of patients with advanced HIV disease, septic shock and multiorgan dysfunction but without respiratory failure. In addition, it provides early in-hospital diagnosis and treatment and comprehensive management in the ICU as determining factors for a good outcome.

KEYWORDS: Histoplasmosis. Sepsis. Septic shock. Multiorgan failure. Intensive care units.

INTRODUCTION

Histoplasmosis is endemic or highly endemic in Latin America, the Caribbean, and North America, where disseminated histoplasmosis (DH) represents the most frequent clinical presentation in individuals with advanced HIV disease¹. DH is a frequent cause of death among individuals with advanced HIV disease from endemic regions, where the best diagnostic and therapeutic resources are usually limited and/or unavailable². Therefore, DH remains neglected, undiagnosed, or misdiagnosed mainly as tuberculosis^{3,4}.

DH usually presents with sub-acute evolution (1–2 months) at the time of diagnosis and can be classified as a mild to moderate or moderate to severe disease. In this category of severity, at least one sign or symptom involving vital organs

and a relevant impairment of general performance status is present¹.

Approximately 10–20% of individuals with AIDS-related DH manifest the severe form of the disease (septic shock with multiorgan dysfunction), with fatality rates reaching up to 50–80%^{4,5}.

We report a case of an individual with advanced HIV disease and severe DH, with a clinical presentation of septic shock, hyperferritinemic syndrome, and multiorgan dysfunction but without respiratory failure, who was successfully treated during an extended hospitalization in the Intensive Care Unit (ICU).

CASE REPORT

A 41-year-old male patient was admitted to a tertiary public hospital in Sao Paulo city, Brazil, with a history of fever, fatigue, weight loss, disseminated skin lesions, low urine output, and mental confusion progressing over

three months. The patient received outpatient treatment for thoracic herpes zoster and was diagnosed with HIV infection three weeks earlier but decided not to initiate antiretroviral therapy. At hospital admission, upon physical examination, he was afebrile and dehydrated, with a blood pressure of 109/72 mmHg, pulse rate of 130 beats/min, and oxygen saturation of 97% on room air. Mental confusion was observed (Glasgow Coma Scale – GCS = 14). The lung sounds were clear upon auscultation, the abdomen was innocent, and there was no peripheral lymphadenopathy, but diffuse maculopapular and crusty skin lesions were noticed (Figure 1A). Laboratory results showed hemoglobin = 13.9 g/dL, white blood cell count = 6,500/mm³, platelet count = 82,000/mm³, C-reactive protein = 26.1 mg/dL, creatinine level = 4.0 mg/dL, sodium concentration = 127 mg/dL, lactate dehydrogenase = 5,782 U/L, aspartate aminotransferase = 342 U/L, alanine aminotransferase = 340 U/L, total bilirubin = 3.9 mg/dL (direct bilirubin = 3.4 mg/dL), international normalized ratio = 1.71,

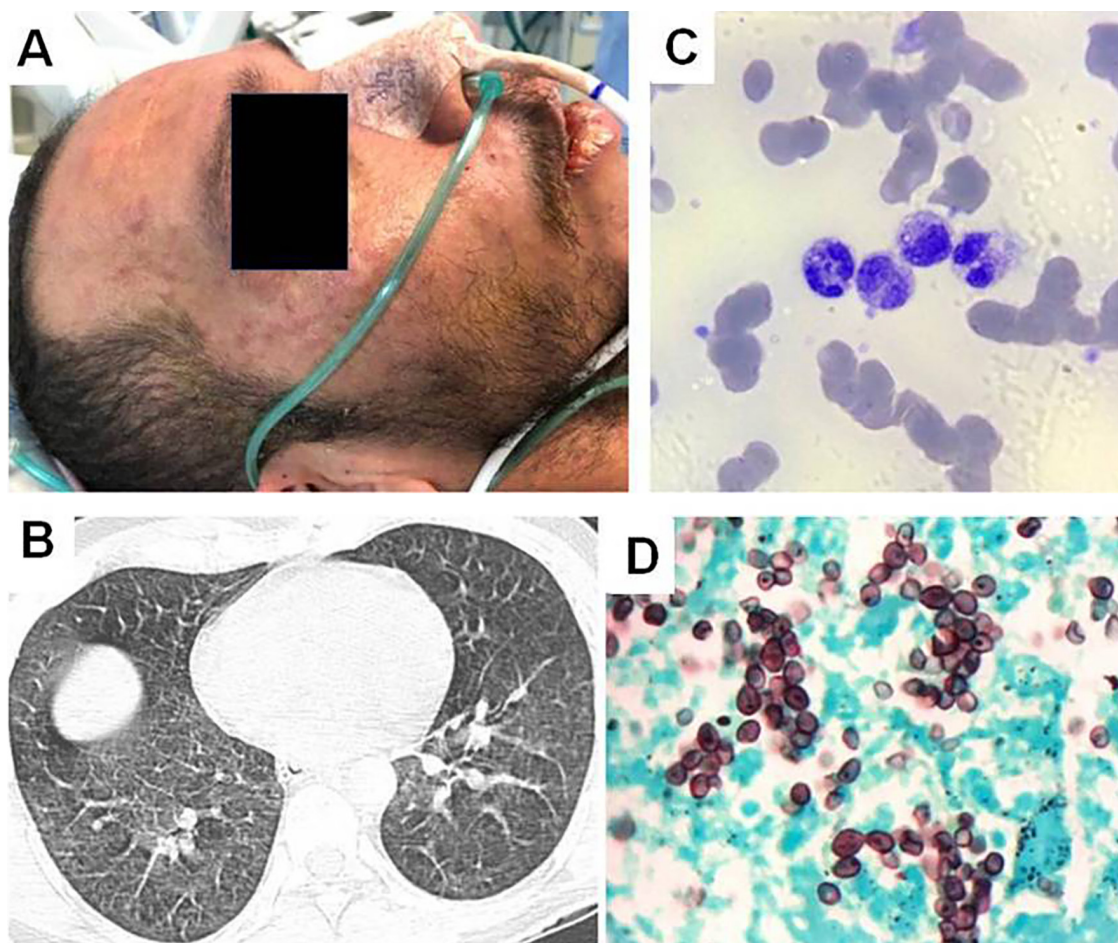


Figure 1 - Photograph of a critically ill patient with disseminated histoplasmosis and advanced HIV showing papules on the face secondary to the fungal disease (A); chest computed tomography showing some small, peripheral and regular non-calcified nodules in the anterior segment of the upper right lobe and in the superior lingular segment (B); Giemsa-stained peripheral blood smear showing yeast-like bodies inside macrophages with morphology suggestive of *Histoplasma spp.* (C); numerous small yeast (2–4 microns in size) with narrow based grouped in clusters inside macrophages (Grocott methenamine silver-stained, 1000X) (D).

triglycerides = 324 mg/dL, and ferritin > 100,000 ng/mL. Serologic diagnosis of HIV-1 infection was confirmed, CD4 count was 4 cells/mm³, and HIV-1 viral load was 1,749,163 copies/mL. The chest computed tomography (CT) showed unspecific findings (Figure 1B). The brain CT scan and the cerebrospinal fluid were normal. The abdominal CT scan showed no hepatosplenomegaly, but some retroperitoneal, periaortic, and interaortocaval lymph node enlargement was identified. On day 1, the sequential organ failure assessment (SOFA) score was 8, and septic shock with multiorgan dysfunction (acute renal failure, metabolic acidosis, hepatic failure, and coagulopathy) was diagnosed.

The primary care team initiated volemic expansion, and ceftriaxone was administered empirically. Yeasts suggestive of *Histoplasma spp.* were observed in the cytoplasm of macrophages of a routine peripheral blood smear (Figure 1C). On day 2, the patient was transferred to the ICU and required supplemental oxygen (1 L/min). Amphotericin B deoxycholate was initiated. On day 3, the SOFA score was 14 and the patient's clinical condition progressed with reduced level of consciousness (GCS 10) and refractory septic shock, requiring high doses of vasopressors, corticosteroids, mechanical ventilation, and hemodialysis. Yeasts suggestive of *Histoplasma spp.* also were observed in the cytoplasm of macrophages in the bone marrow and skin samples (Figure 1D) on days 3 and 7, respectively. Hemophagocytosis was not observed in the bone marrow. After four weeks of incubation, peripheral blood and bone marrow samples cultures revealed *Histoplasma spp.* Aerobic, anaerobic, and mycobacterial blood and bone marrow cultures were all negative. In addition, Xpert MTB/RIF Ultra assay, mycobacterial cultures, and acid-fast bacillus smear from tracheal secretion were negative. The patient stayed in the ICU for 32 days, receiving empiric broad-spectrum antibiotic therapy and frequent blood and platelet transfusions. Treatment with amphotericin B was extended to 23 days (20 days with amphotericin B deoxycholate and 3 days with liposomal amphotericin B). Antiretroviral therapy was initiated on day 10. After progressive clinical improvement and most laboratory test results returned to normal, the patient was discharged from the hospital with no need for dialysis and an early follow-up in the outpatient clinic of our hospital. Eight months after the discharge, he is fully active and able to perform all pre-hospitalization activities without restrictions. The recent laboratory results showed mild abnormality of kidney function (creatinine level = 1.3 mg/dL), CD4 count = 180 cells/mm³, and HIV-1 viral load < 40 copies/mL. In addition, the patient is maintaining regular use of darunavir/ritonavir, dolutegravir, lamivudine, prophylactic trimethoprim-sulfamethoxazole and itraconazole.

DISCUSSION

We report a case of septic shock, hyperferritinemic syndrome, and multiorgan dysfunction without respiratory failure in a patient with DH and advanced HIV disease, successfully treated after an extended hospitalization in the ICU.

Disseminated histoplasmosis has arisen alongside the AIDS initial reports in regions where this mycosis is endemic⁶, and it was considered early-on as an AIDS-defining condition in the classification of the US Centers for Disease Control and Prevention⁷.

Histoplasmosis has been described as a mild-to-moderate lung disease in people living with HIV (PLWHIV) without advanced disease, which is similar to the clinical presentation observed in immunocompetent individuals⁸. In contrast, the disseminated disease is the most common presentation (> 95%) in patients with advanced HIV disease⁴. Interestingly, a recent study evaluating a rapid screening program for AIDS-related opportunistic diseases in an endemic area of histoplasmosis suggested a benefit in testing for histoplasmosis in all newly diagnosed HIV patients with a CD4 cell count < 350 cells/mm³⁹.

Most patients with DH and advanced HIV disease present fever, fatigue, and weight loss. Pulmonary manifestations are the most frequent localizing symptoms (~50%), usually associated with diffuse radiological infiltrates. Other findings include abdominal pain, diarrhea, lymph node enlargement, hepatosplenomegaly, and mucocutaneous manifestations⁴. The spectrum of presentations of DH is broad, and a high index of suspicion is needed. Our patient presented with several manifestations of DH, except for respiratory and gastrointestinal complaints, and hepatosplenomegaly.

Natural history of AIDS-related DH can show a severe and life-threatening disease with mortality as high as 50–80%, despite adequate antifungal therapy^{4,5}. Severe DH includes septic shock, acute respiratory distress, hepatic and renal failure, altered mental status, coagulopathy, and hemophagocytic syndrome^{4,10}. In the general population, most patients with septic shock manifest acute respiratory distress. Our patient presented diverse complications of severe DH except for acute respiratory distress.

Hyperferritinemic syndrome comprises diseases with similar clinical and pathogenic features associated with very high ferritin levels. These diseases include septic shock; macrophage activation syndrome or hemophagocytic lymphohistiocytosis (HLH) described as a potentially life-threatening complication of autoimmune diseases; adult-onset Still's disease; and catastrophic antiphospholipid syndrome¹¹. The highly increased ferritin levels observed in

our patient can be hypothetically explained by the aberrant response to inflammation and septic shock¹².

Hemophagocytic lymphohistiocytosis can be classified as possible (4 of the 8 common symptoms of the disease) or confirmed (5 of 8 symptoms) according to the following criteria: (1) fever; (2) splenomegaly; (3) cytopenias affecting 2/3 cell lines of the peripheral blood; (4) hypertriglyceridemia and/or hypofibrinogenemia; (5) hemophagocytosis in the spleen, bone marrow, or lymph nodes, with no evidence of malignancy; (6) low or absent NK cell activity (not available at our facility); (7) ferritin > 500 ng/dL; and (8) soluble IL-2 receptor > 2,400 U/mL¹³. Our patient had fever, high ferritin levels (> 100,000 ng/mL), and hypertriglyceridemia (324 mg/dL). There was no hemophagocytosis in the bone marrow; splenomegaly; cytopenia of two lineages (only thrombocytopenia); or fibrinogen consumption. In addition, NK cell activity and soluble IL-2 receptor were unavailable at our facility. Thus, our patient did not meet the criteria for possible or confirmed HLH. In contrast, the histoplasmosis-induced hemophagocytic syndrome has been previously described and it is important to highlight that the absence of hemophagocytosis does not exclude the diagnosis of HLH¹⁴. A recent study carried out in our hospital identified *Mycobacterium spp.*, *Cytomegalovirus*, and *Cryptococcus neoformans* as the primary triggers of hemophagocytic syndrome in PLWHIV. *Histoplasma* was not identified in any case¹².

AIDS-related diseases (e.g., tuberculosis) and bacterial infections (e.g., pneumonia and bacteremia) continue to be leading causes of hospital admission and in-hospital mortality among PLWHIV worldwide¹⁵. Similarly, tuberculosis (pulmonary or disseminated) and bacterial pneumonia are important causes of community-acquired sepsis in patients with advanced HIV disease. Our case emphasizes histoplasmosis as an important differential diagnosis in the context of sepsis, septic shock, and multiorgan dysfunction in this population, despite the absence of respiratory clinical and radiological findings.

Hospitalized patients with advanced HIV disease usually present fatigue, weight loss, and more than one opportunistic disease. These characteristics can hinder the initial approach due to the plethora of simultaneous and/or similar clinical manifestations of different infections. This fact is common in PLWHIV with DH, of which ~40% of the cases had a concomitant opportunistic infection (e.g., esophageal candidiasis, chronic herpes, tuberculosis, cerebral toxoplasmosis)¹⁶. On the contrary, our patient did not have an opportunistic infection concomitant with histoplasmosis.

In endemic areas such as Latin America and the Caribbean, the burden of histoplasmosis is estimated to have

a similar or even higher incidence¹⁷ than tuberculosis when the CD4 cell count is < 50 cells/mm³¹⁸. In this scenario, DH is usually misdiagnosed as disseminated tuberculosis.

The World Health Organization (WHO) recommends the antigen detection assay to diagnose DH among PLWHIV due to its high accuracy and simplicity to use in low- and middle-income countries¹. However, this method is usually unavailable in these countries, including Latin America, where conventional mycological methods are the most commonly used in referral centers. *Histoplasma* antigen testing increases the diagnostic yield by ~50%, compared with standard mycology methods, among PLWHIV with DH¹⁹. In clinical practice, *Histoplasma* antigen assay contributes to the diagnosis of DH and works as a complement to the conventional mycological methods²⁰. A recent survey showed that only 9% of health centers from Latin America and the Caribbean could have the potential to apply for the minimum standards in mycology, as determined by the European Confederation of Medical Mycology¹⁸. This reality claims an urgent need to improve diagnostic conditions in the region. Fortunately, the diagnosis of our patient was obtained early in a peripheral blood smear.

Severe or moderately severe histoplasmosis is defined as the presence of at least one sign or symptom involving vital organs (respiratory or circulatory failure, neurological signs, renal failure, coagulation anomalies, and a general alteration of WHO performance status greater than 2)¹. Our patient presented most of the alterations of the severe form, including kidney compromise at the moment of diagnosis.

WHO recommends liposomal amphotericin B as the preferred therapy for severe DH among PLWHIV¹. However, this medication is usually unavailable in low- and middle-income countries. Our patient presented renal failure as part of multiorgan dysfunction caused by DH and received amphotericin B deoxycholate, requiring hemodialysis. The treatment may have contributed to the extended need for hemodialysis, but it was not the initial factor triggering renal failure. In this case, the positive outcomes in the short and long terms can be justified mainly by the multidisciplinary and advanced support, but other variables may also have contributed (patient's age, early diagnosis, and antifungal therapy after hospital admission, and the absence of respiratory involvement).

CONCLUSION

In conclusion, our case highlights the importance of including DH in the differential diagnosis of patients with advanced HIV disease presenting with community-acquired sepsis and multiorgan dysfunction, but without respiratory

failure. Furthermore, this case reinforces the importance of early diagnosis and treatment after hospital admission and how the comprehensive management in the ICU brought a positive outcome.

REFERENCES

1. Pan American Health Organization, World Health Organization. Guidelines for diagnosing and managing disseminated histoplasmosis among people living with HIV. Washington: PAHO: WHO; 2020. [cited 2023 Jan 27]. Available from: <https://www.who.int/publications/i/item/9789240006430>
2. Adamian CM, Lima Mota MA, Martins AA, Aragão MC, Carvalho MS, Meneses GC, et al. Progressive disseminated histoplasmosis in HIV-positive patients. *Int J STD AIDS*. 2022;33:544-53.
3. Nacher M, Adenis A, Aznar C, Blanchet D, Vantilcke V, Demar M, et al. How many have died from undiagnosed human immunodeficiency virus-associated histoplasmosis, a treatable disease? Time to act. *Am J Trop Med Hyg*. 2014;90:193-4.
4. Limper AH, Adenis A, Le T, Harrison TS. Fungal infections in HIV/AIDS. *Lancet Infect Dis*. 2017;17:e334-43.
5. Wheat J, Sarosi G, McKinsey D, Hamill R, Bradsher R, Johnson P, et al. Practice guidelines for the management of patients with histoplasmosis. *Clin Infect Dis*. 2000;30:688-95.
6. Holmberg K, Meyer RD. Fungal infections in patients with AIDS and AIDS-related complex. *Scand J Infect Dis*. 1986;18:179-92.
7. Centers for Disease Control. Classification system for human T-lymphotropic virus type III/lymphadenopathy-associated virus infections. *MMWR Morb Mortal Wkly Rep*. 1986;35:334-9.
8. Baddley JW, Sankara IR, Rodriguez JM, Pappas PG, Many WJ Jr. Histoplasmosis in HIV-infected patients in a southern regional medical center: poor prognosis in the era of highly active antiretroviral therapy. *Diagn Microbiol Infect Dis*. 2008;62:151-6.
9. Medina N, Alastruey-Izquierdo A, Bonilla O, Gamboa O, Mercado D, Pérez JC, et al. A rapid screening program for histoplasmosis, tuberculosis, and cryptococcosis reduces mortality in HIV patients from Guatemala. *J Fungi (Basel)*. 2021;7:268.
10. Wheat LJ, Connolly-Stringfield PA, Baker RL, Curfman MF, Eads ME, Israel KS, et al. Disseminated histoplasmosis in the acquired immune deficiency syndrome: clinical findings, diagnosis and treatment, and review of the literature. *Medicine (Baltimore)*. 1990;69:361-74.
11. Rosário C, Zandman-Goddard G, Meyron-Holtz EG, D'Cruz DP, Shoenfeld Y. The hyperferritinemic syndrome: macrophage activation syndrome, Still's disease, septic shock and catastrophic antiphospholipid syndrome. *BMC Med*. 2013;11:185.
12. Telles JP, Andrade Perez M, Marcusso R, Correa K, Teixeira RF, Tobias WM. Hemophagocytic syndrome in patients living with HIV: a retrospective study. *Ann Hematol*. 2019;98:67-72.
13. Henter JI, Horne A, Aricó M, Egeler RM, Filipovich AH, Imashuku S, et al. HLH-2004: diagnostic and therapeutic guidelines for hemophagocytic lymphohistiocytosis. *Pediatr Blood Cancer*. 2007;48:124-31.
14. Townsend JL, Shanbhag S, Hancock J, Bowman K, Nijhawan AE. Histoplasmosis-induced hemophagocytic syndrome: a case series and review of the literature. *Open Forum Infect Dis*. 2015;2:ofv055.
15. Ford N, Shubber Z, Meintjes G, Grinsztejn B, Eholie S, Mills EJ, et al. Causes of hospital admission among people living with HIV worldwide: a systematic review and meta-analysis. *Lancet HIV*. 2015;2:e438-44.
16. Nacher M, Valdes A, Adenis A, Blaizot R, Abboud P, Demar M, et al. Disseminated histoplasmosis in HIV-infected patients: a description of 34 years of clinical and therapeutic practice. *J Fungi (Basel)*. 2020;6:164.
17. Adenis AA, Valdes A, Cropet C, McCotter OZ, Derado G, Couppie P, et al. Burden of HIV-associated histoplasmosis compared with tuberculosis in Latin America: a modelling study. *Lancet Infect Dis*. 2018;18:1150-9.
18. Falci DR, Pasqualotto AC. Clinical mycology in Latin America and the Caribbean: a snapshot of diagnostic and therapeutic capabilities. *Mycoses*. 2019;62:368-73.
19. Falci DR, Monteiro AA, Caurio CF, Magalhães TC, Xavier MO, Basso RP, et al. Histoplasmosis, an underdiagnosed disease affecting people living with HIV/AIDS in Brazil: results of a multicenter prospective cohort study using both classical mycology tests and histoplasma urine antigen detection. *Open Forum Infect Dis*. 2019;6:ofz073.
20. Vidal JE, Werlang PC, Muniz BM, Rego CM, Barbalho RE, Baptista AM, et al. Combining urine antigen and blood polymerase chain reaction for the diagnosis of disseminated histoplasmosis in hospitalized patients with advanced HIV disease. *Med Mycol*. 2021;59:916-22.